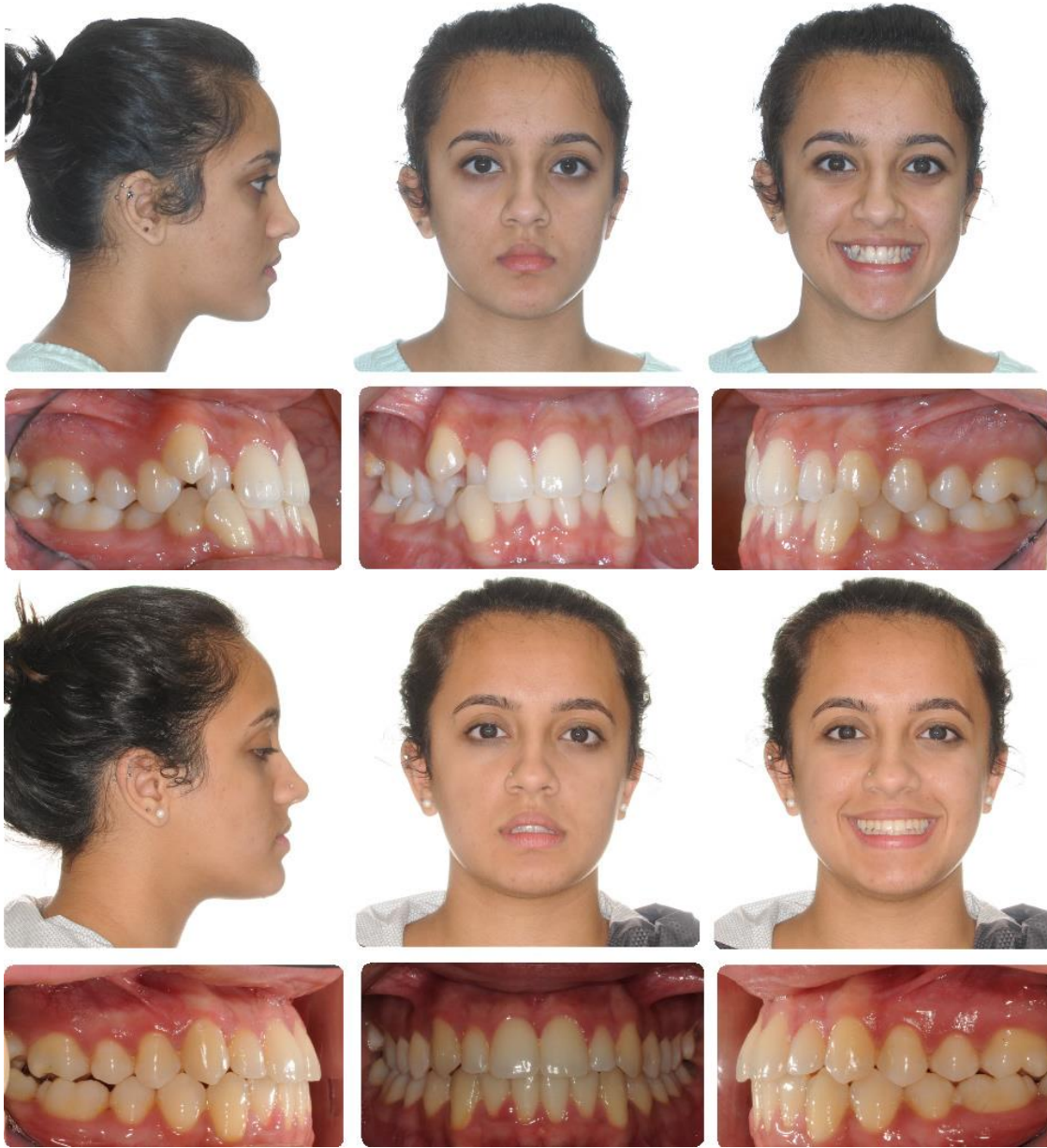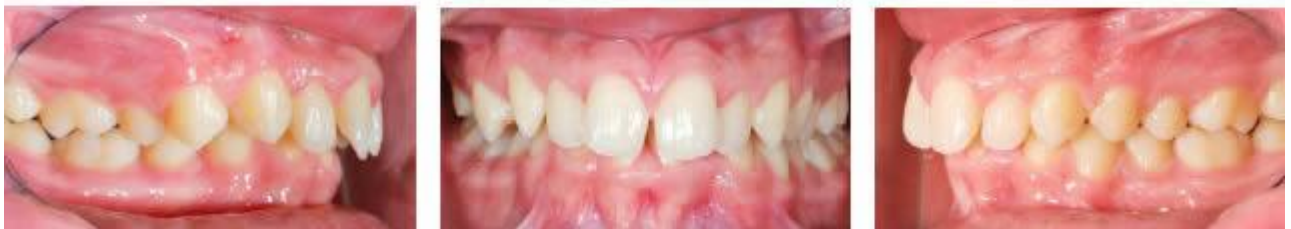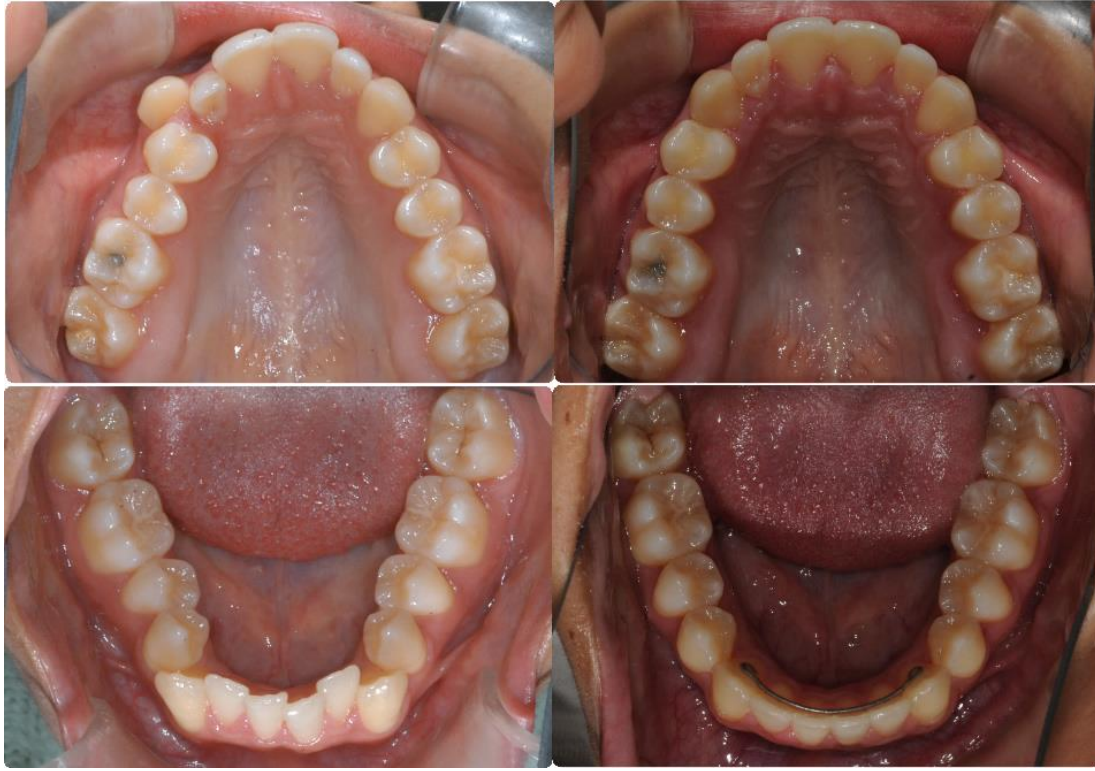


## Non -extraction cases

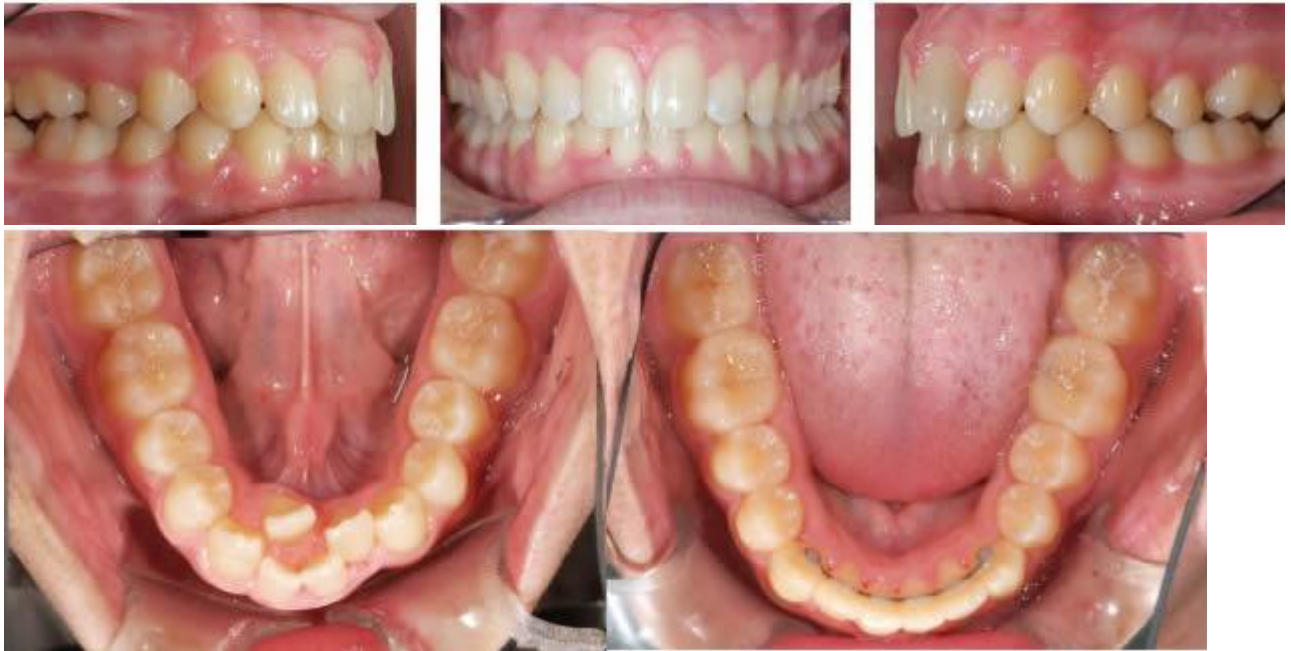

15 months full braces



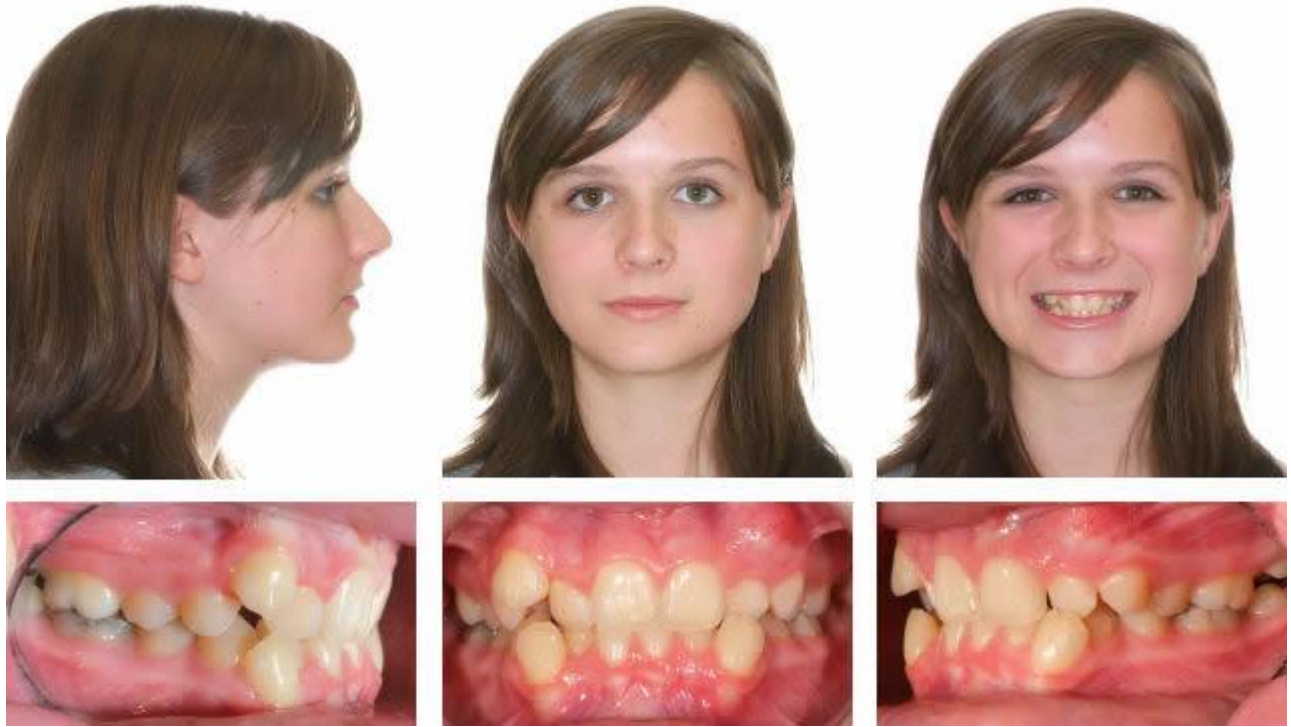Initial



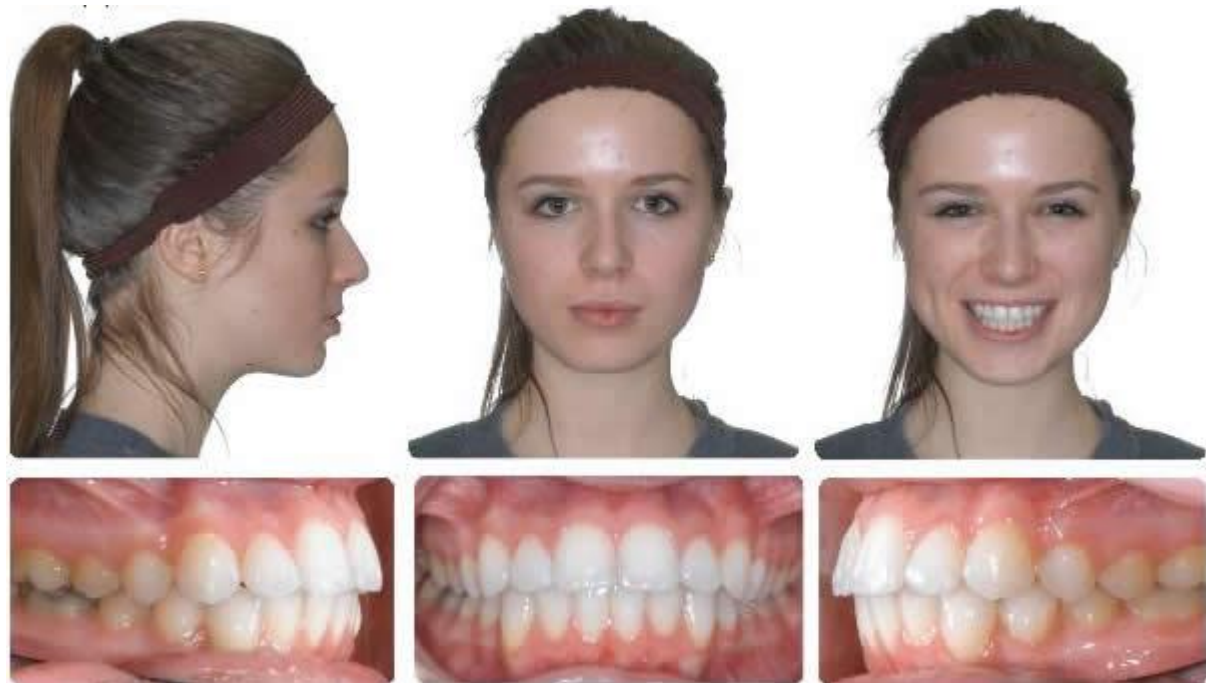

18 months full braces

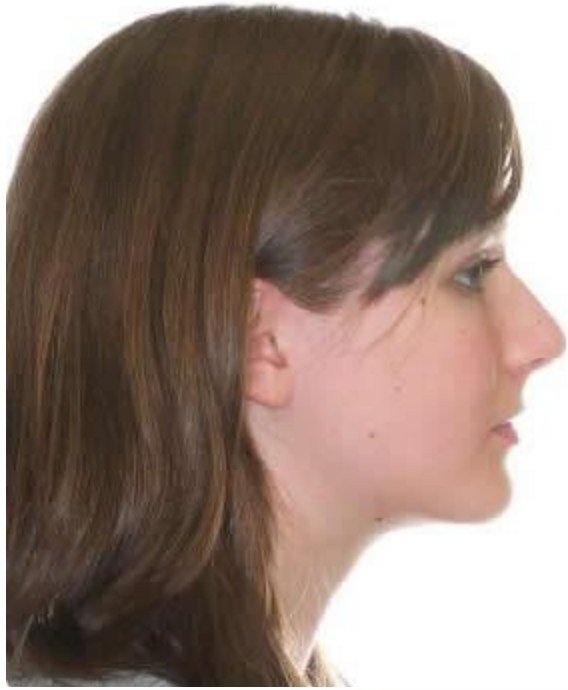---



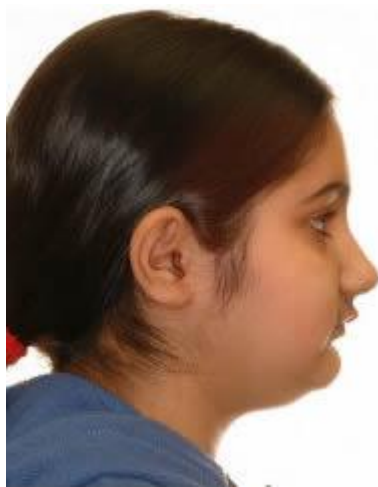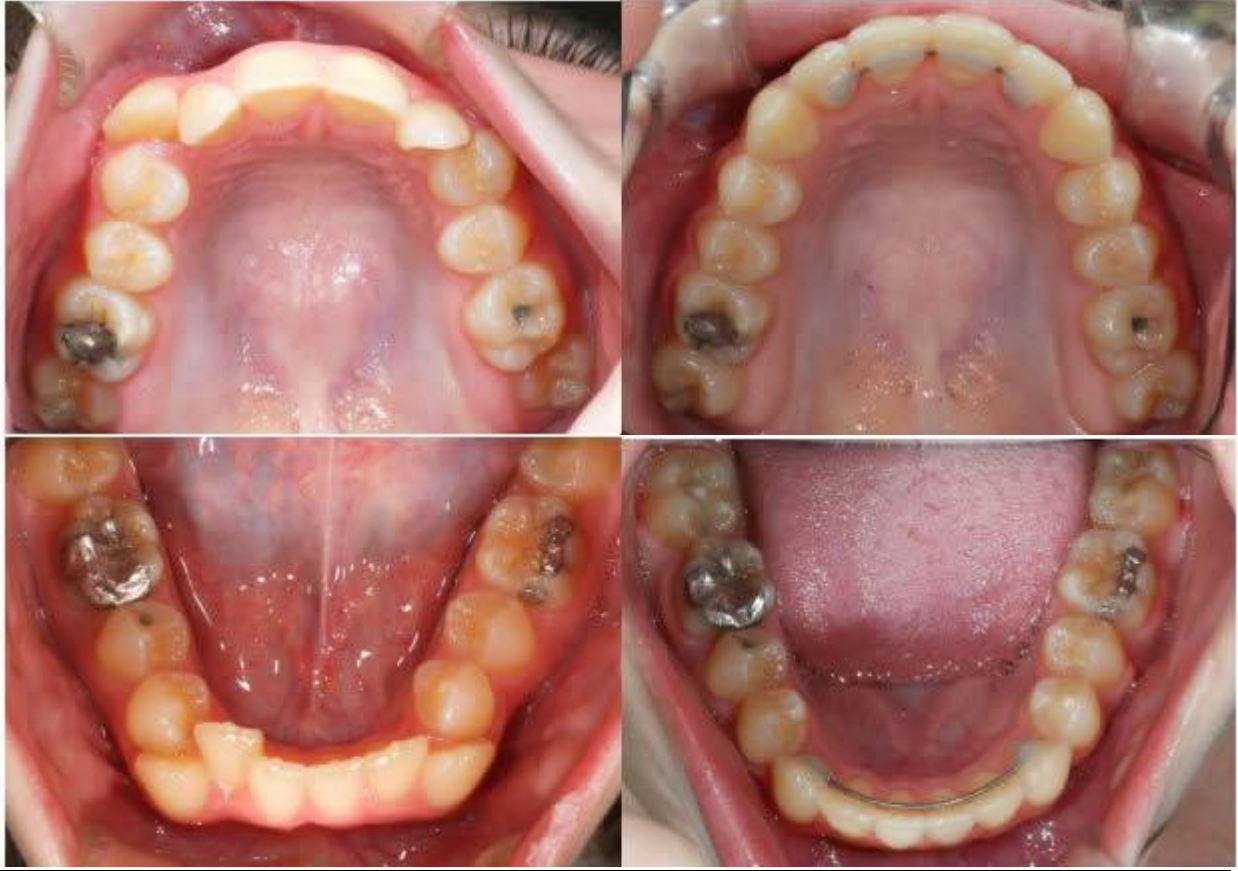Initial



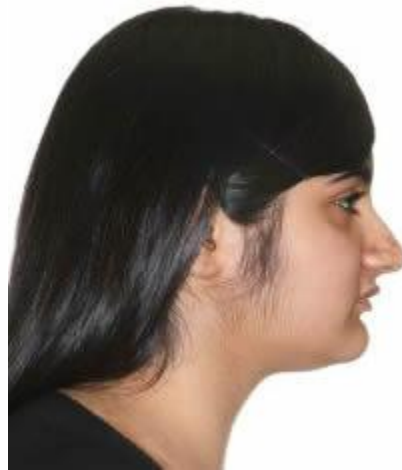18 months full braces including surgical exposure of the maxillary left canine, 9 months after deband



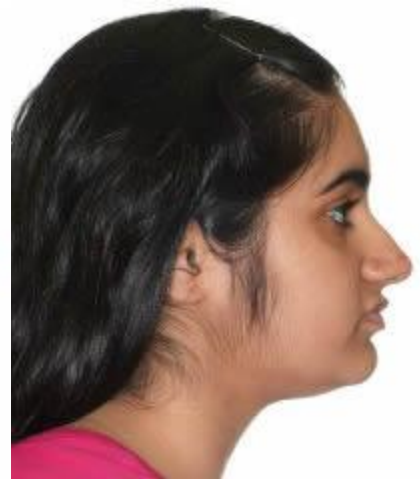



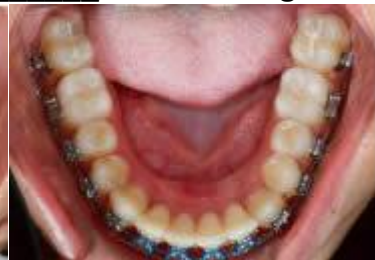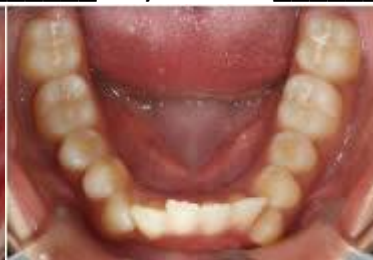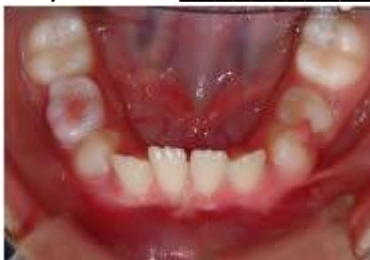10 years old



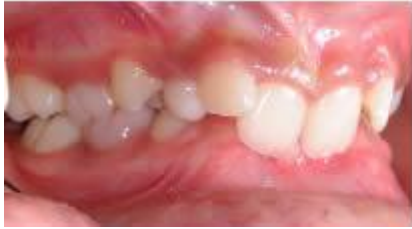16 years old



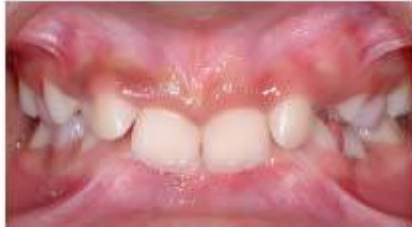5 months alignment



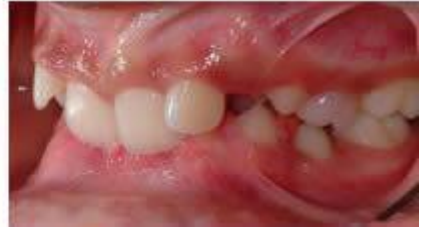10 years old



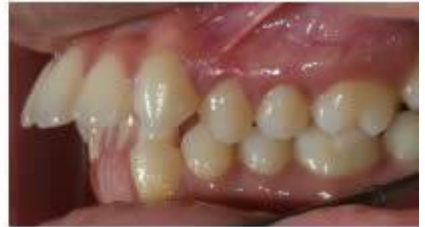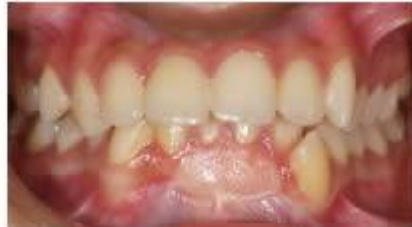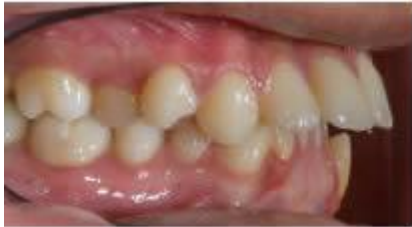16 years old



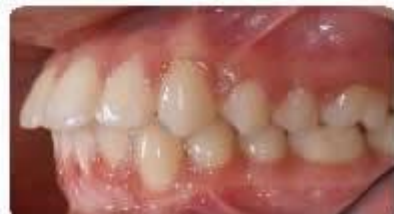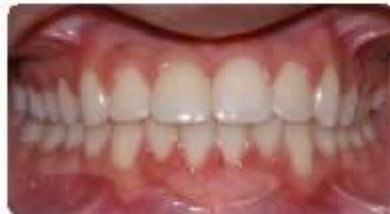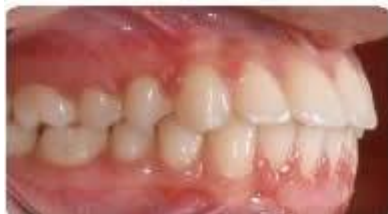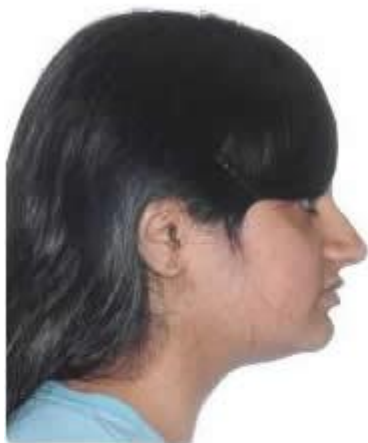5 months alignment



10 years old

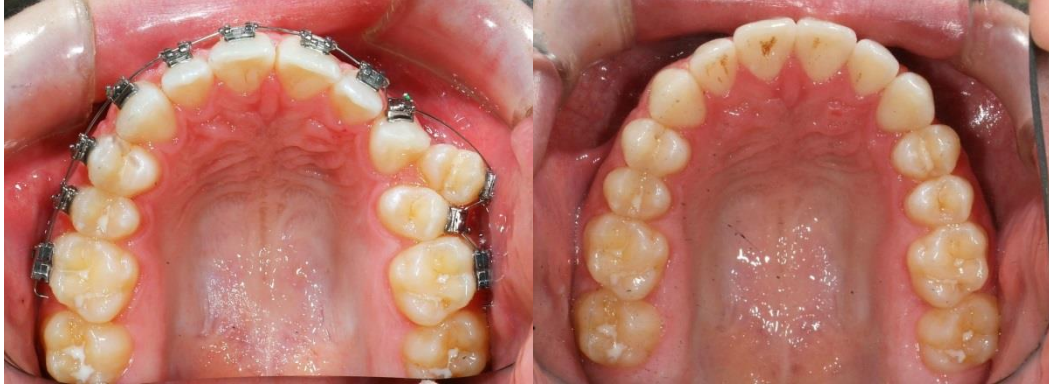

16 years old



14 months braces, normal incisor proclination for a short lower facial height patient

The following case shows alignment of an ectopically erupted upper left first bicuspid. There was no open coil springs used.



Day of indirect bonding and placement of .012niti \_\_\_\_\_ Final