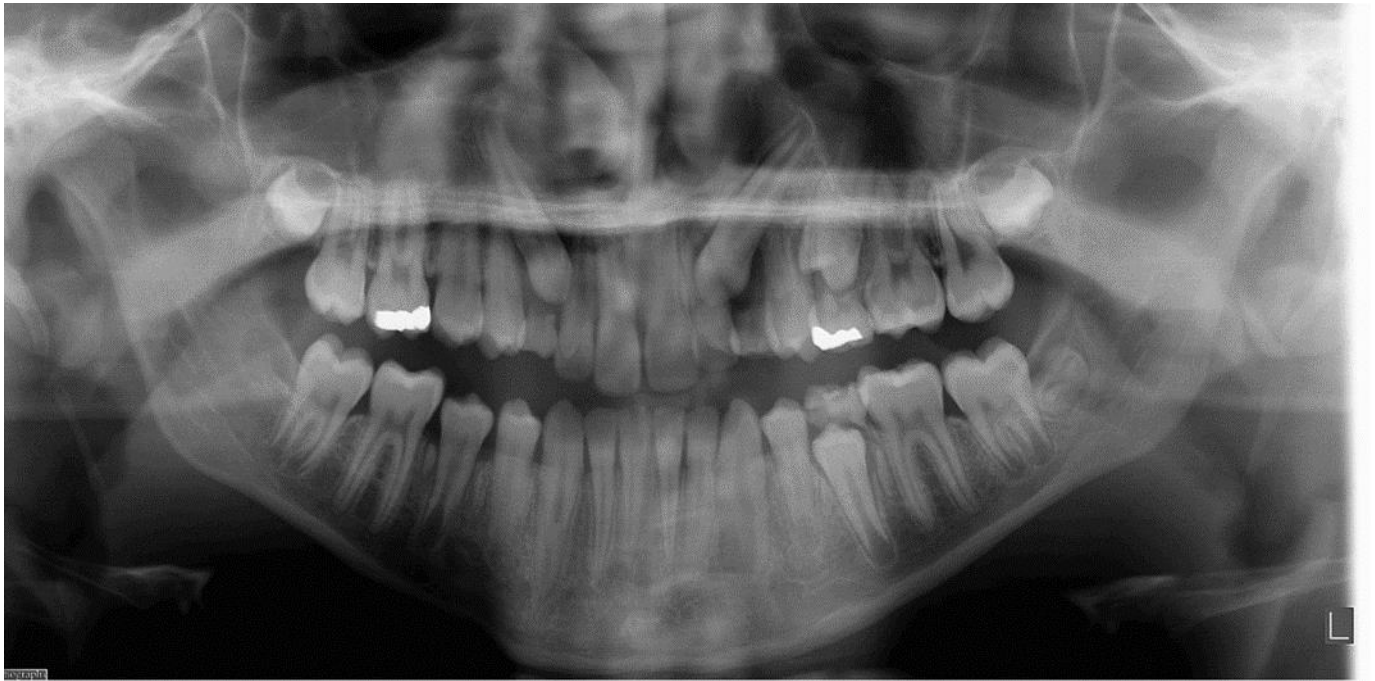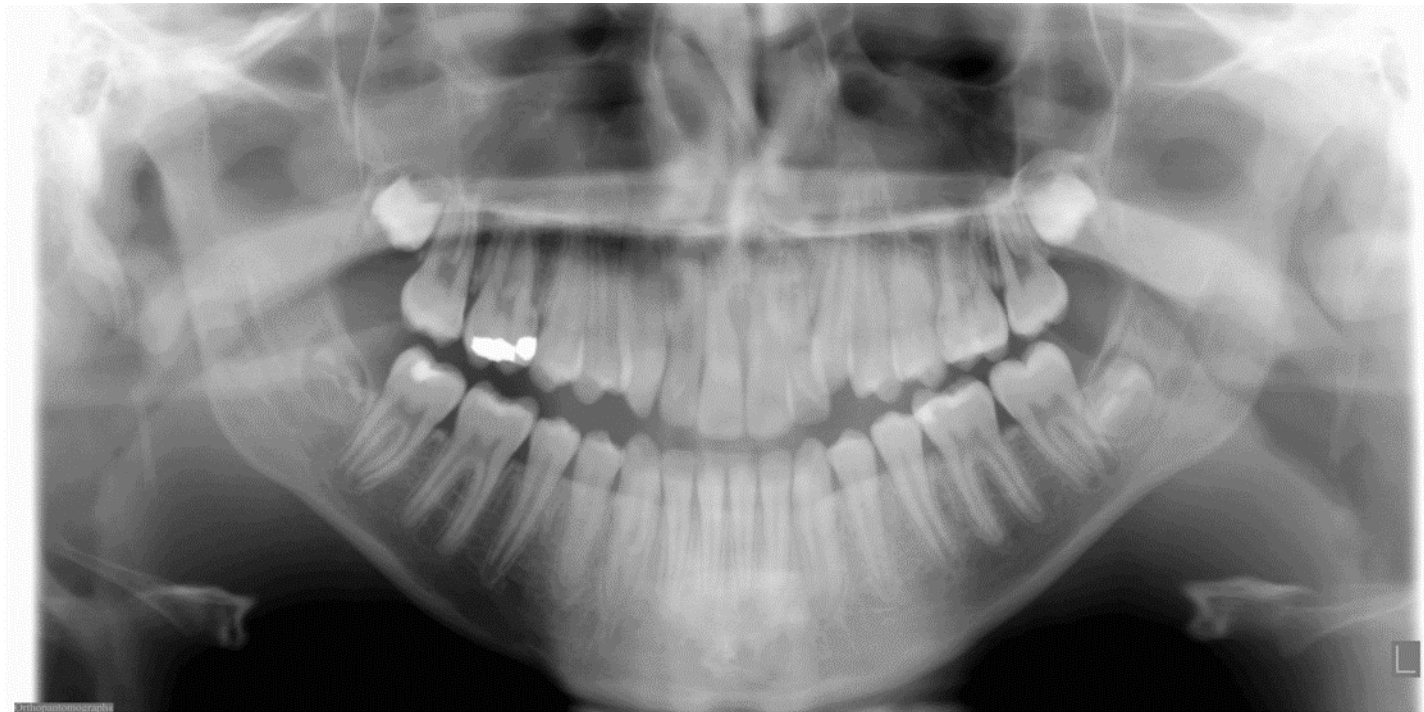


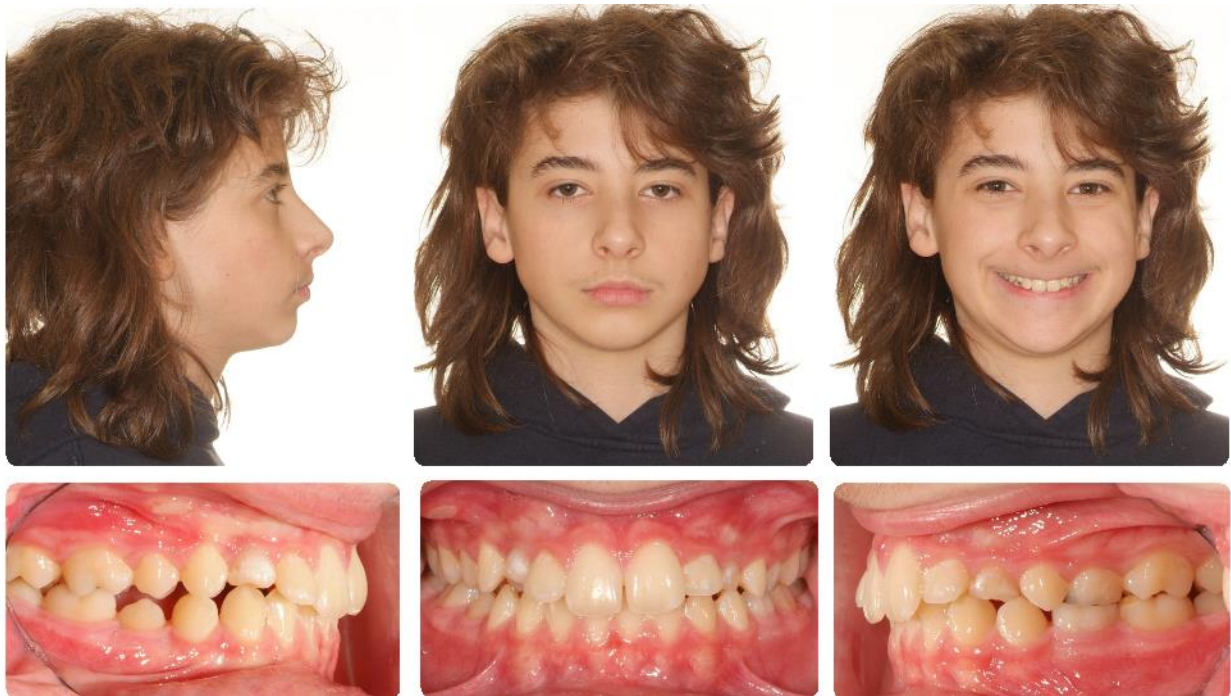## Impacted Canines: A Case for Crossbow



Before Xbow, mesially impacted canines

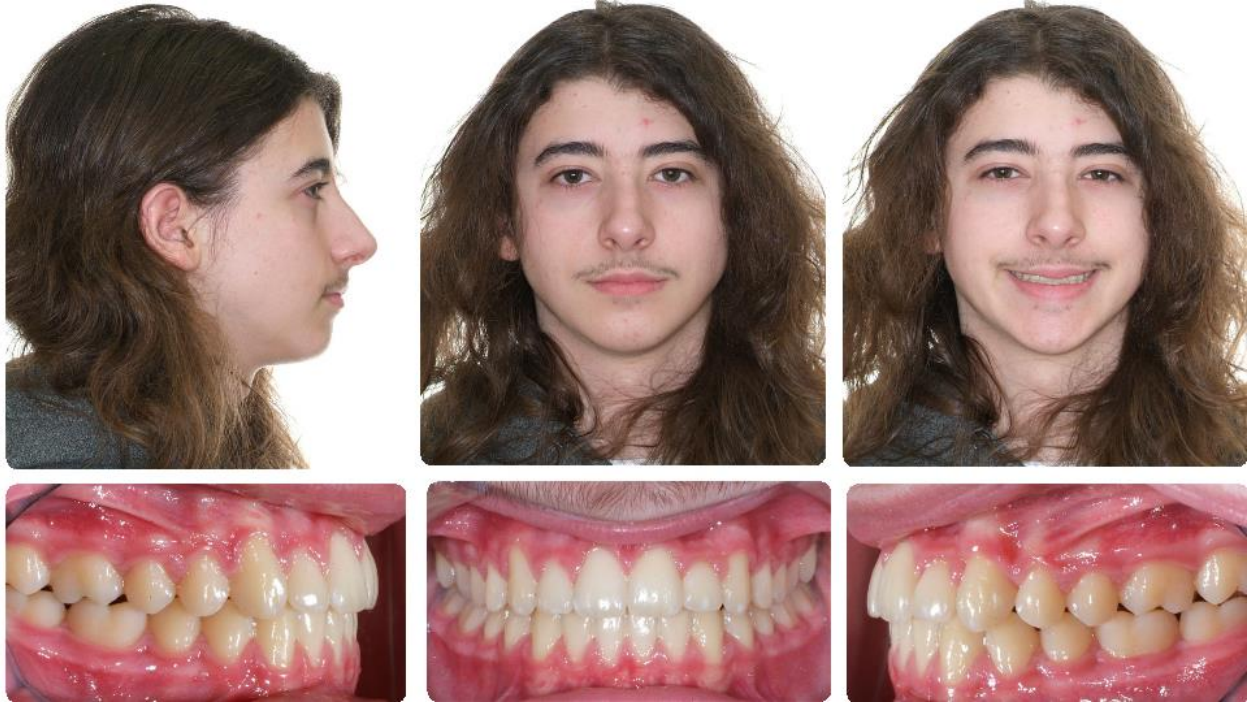

After Xbow, primary canines were extracted, but the canines were not surgically exposed and brackets had not been placed yet.

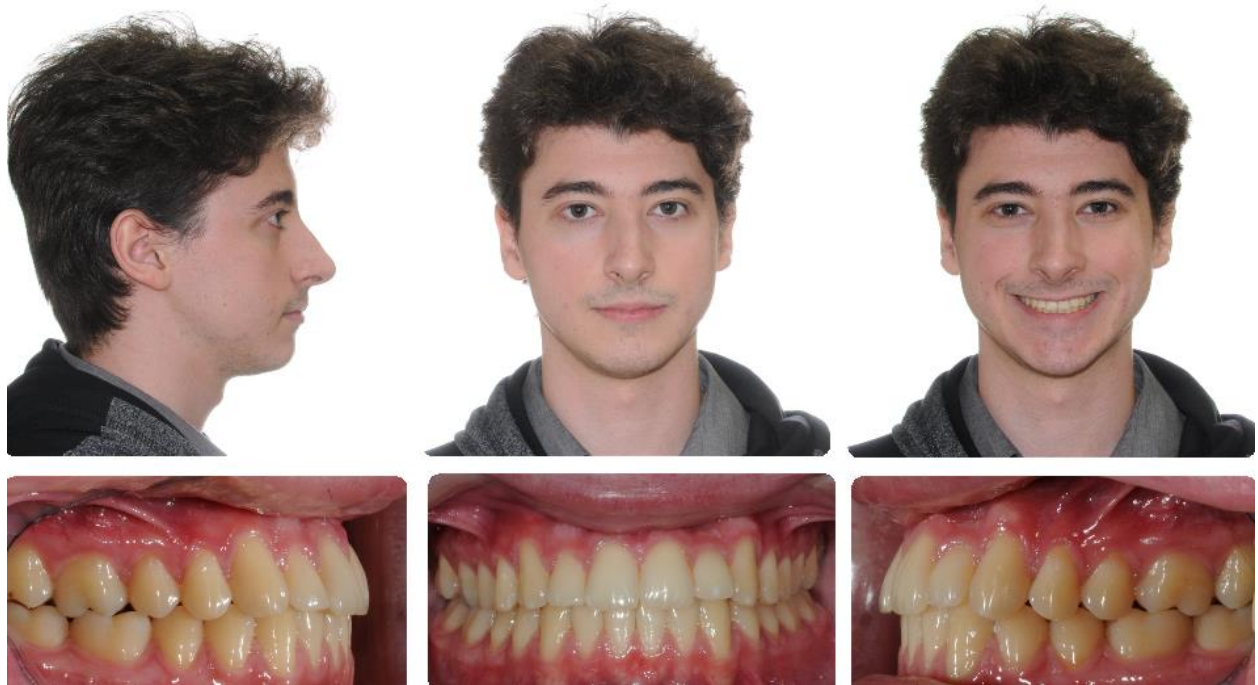

Even though the bicuspid relationship was Class I on the left we still used the spring for 3 months to over-correct to a half cusp Class III. The right spring was used for 5 months in order to over-correct the bicuspid relationship from a half cusp Class II to a half cusp Class III. Distalizing the first bicuspids opens space for the canines and stretches the transeptal fibers between the canines and first bicuspids, resulting in distal traction and eruption of the canines.





After 12 months full edgewise appliance



6 years post deband