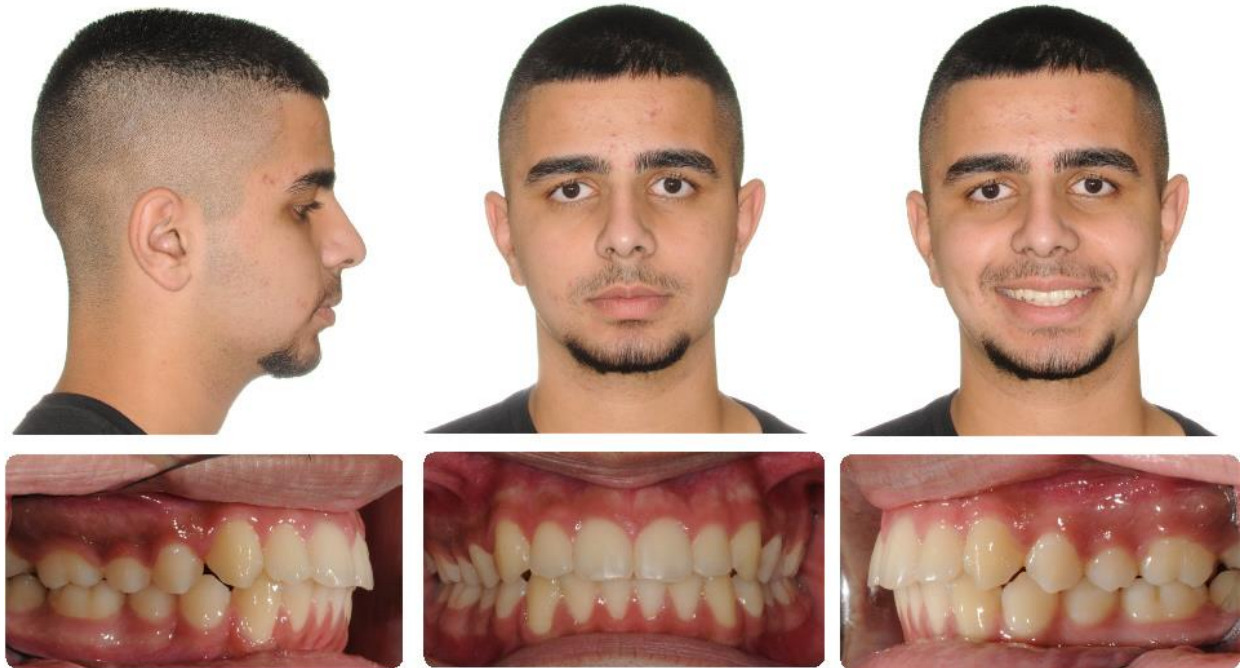
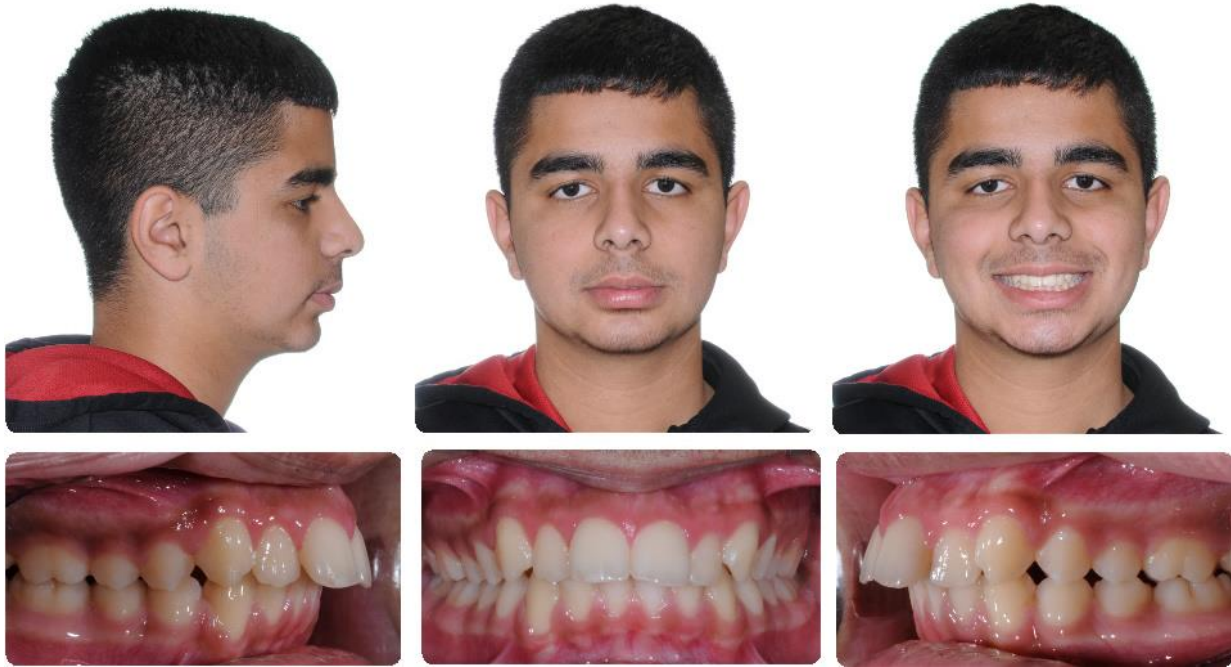
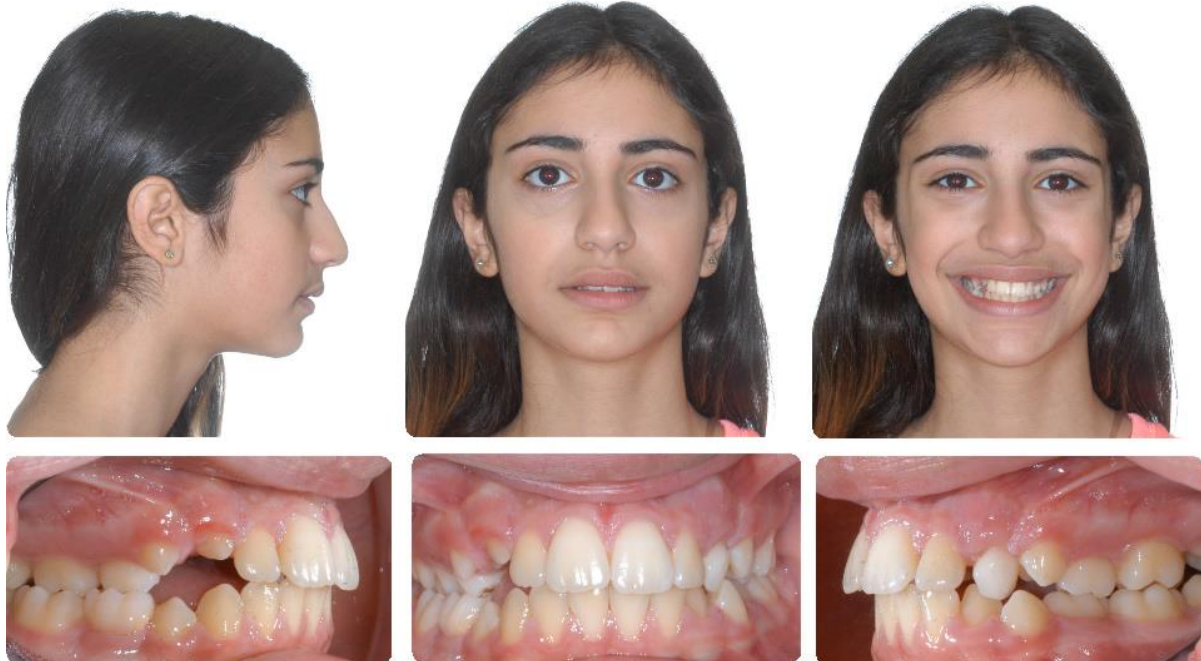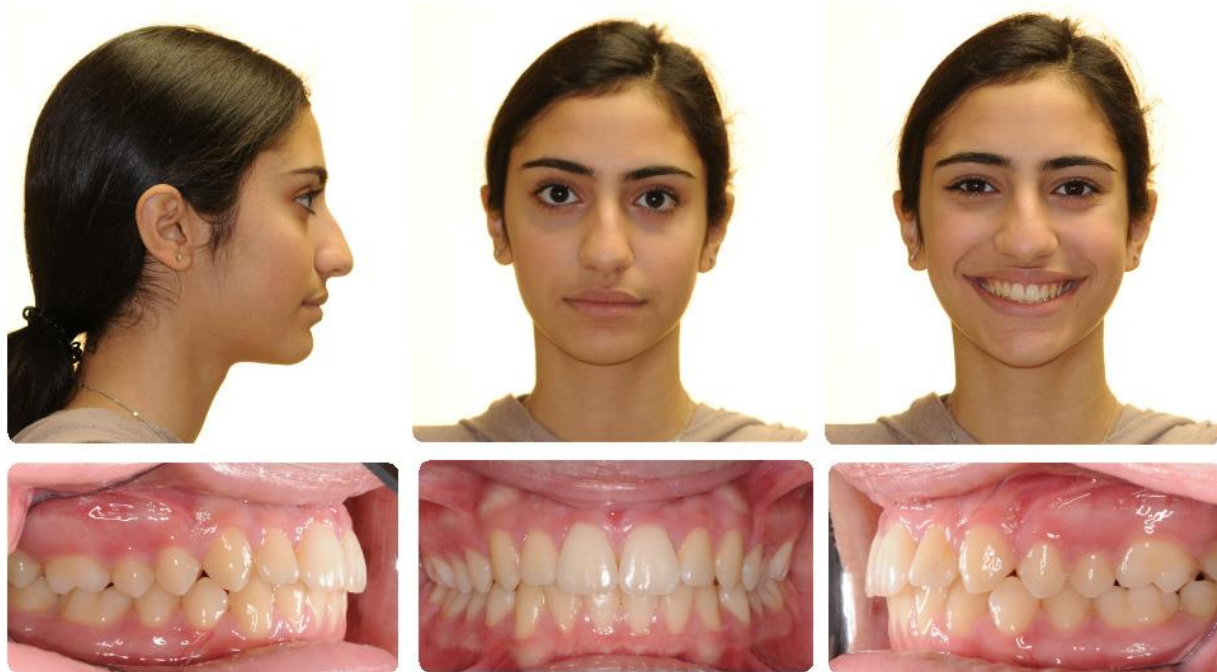Completed One Phase Only Cases



1. RME X 6 2. Xbow (springs for 3 months)

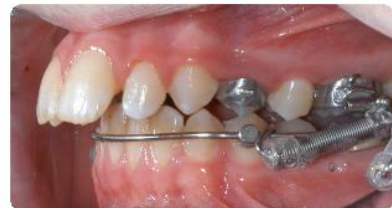
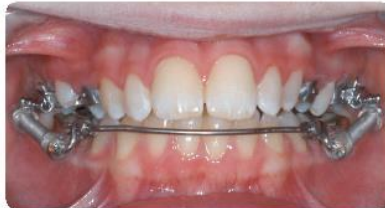
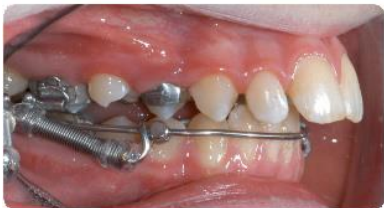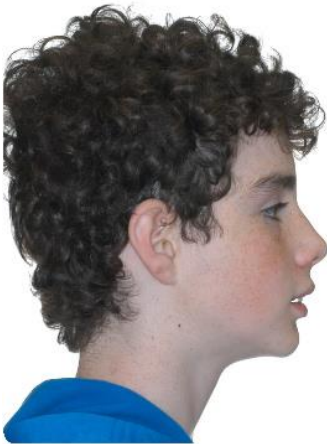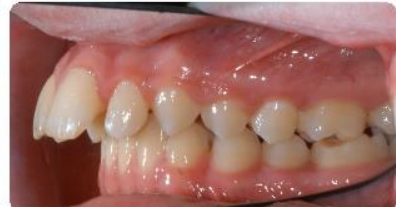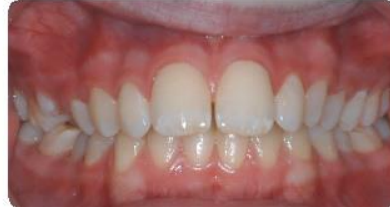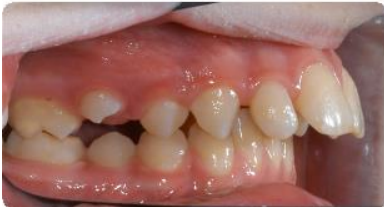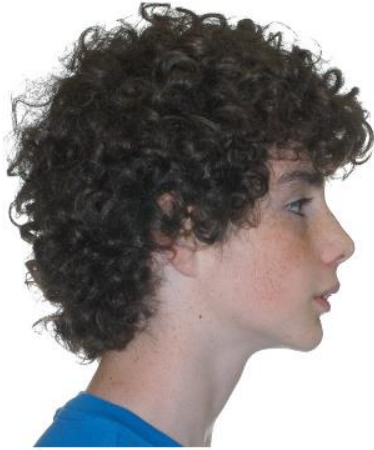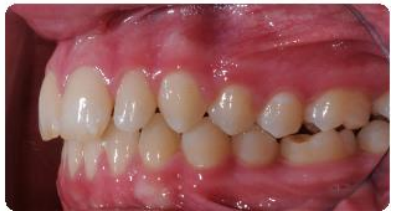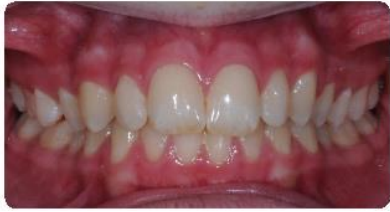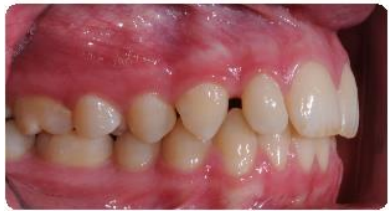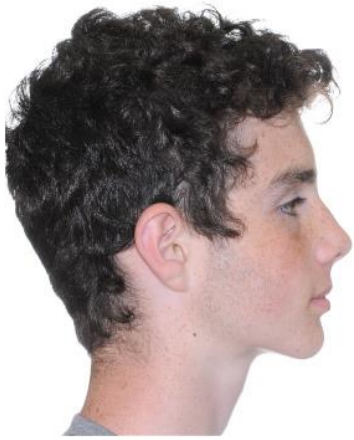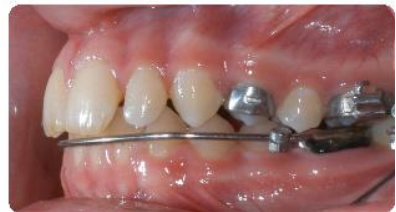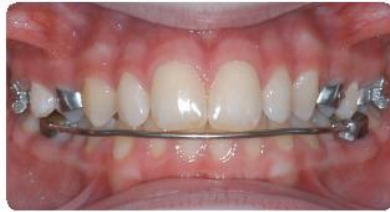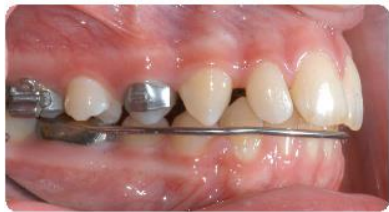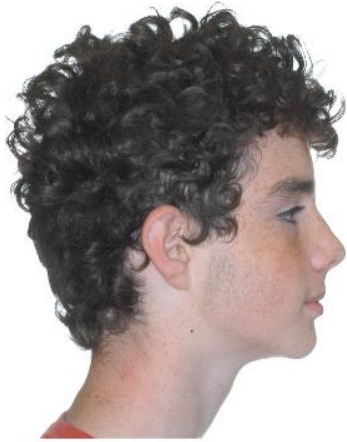Initial

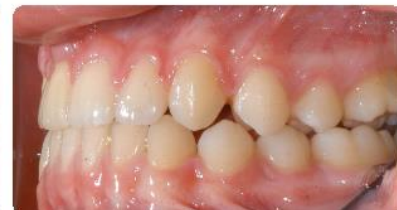
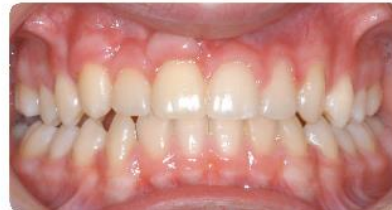
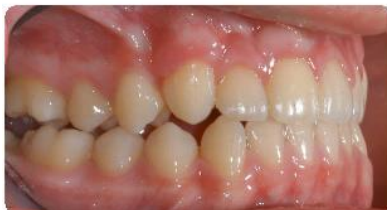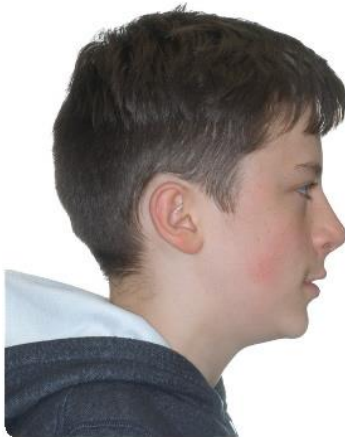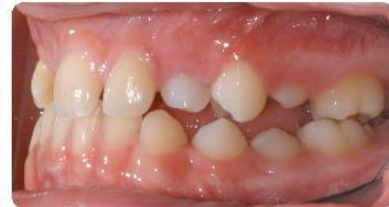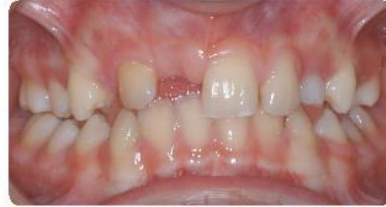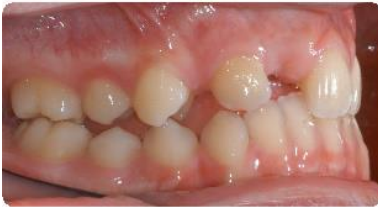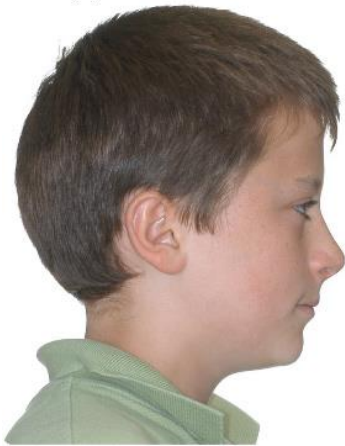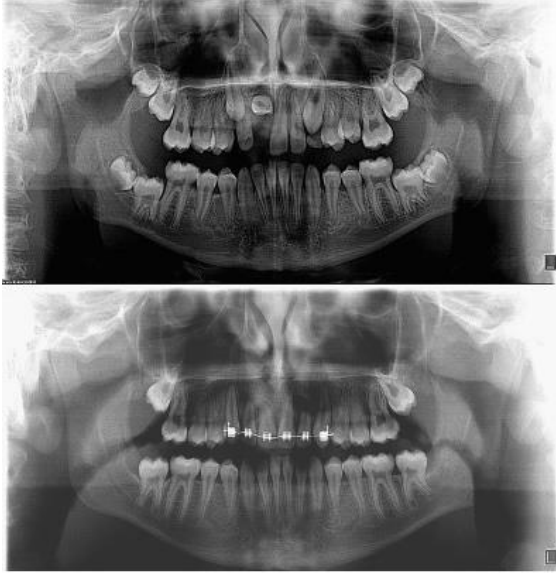
1.RME 2. Xbow with springs for 3 months. 3. RME (part of Xbow) Photos taken one year after Xbow removal. No braces used.

This is an example of a unilateral crossbite and asymmetric Class II.

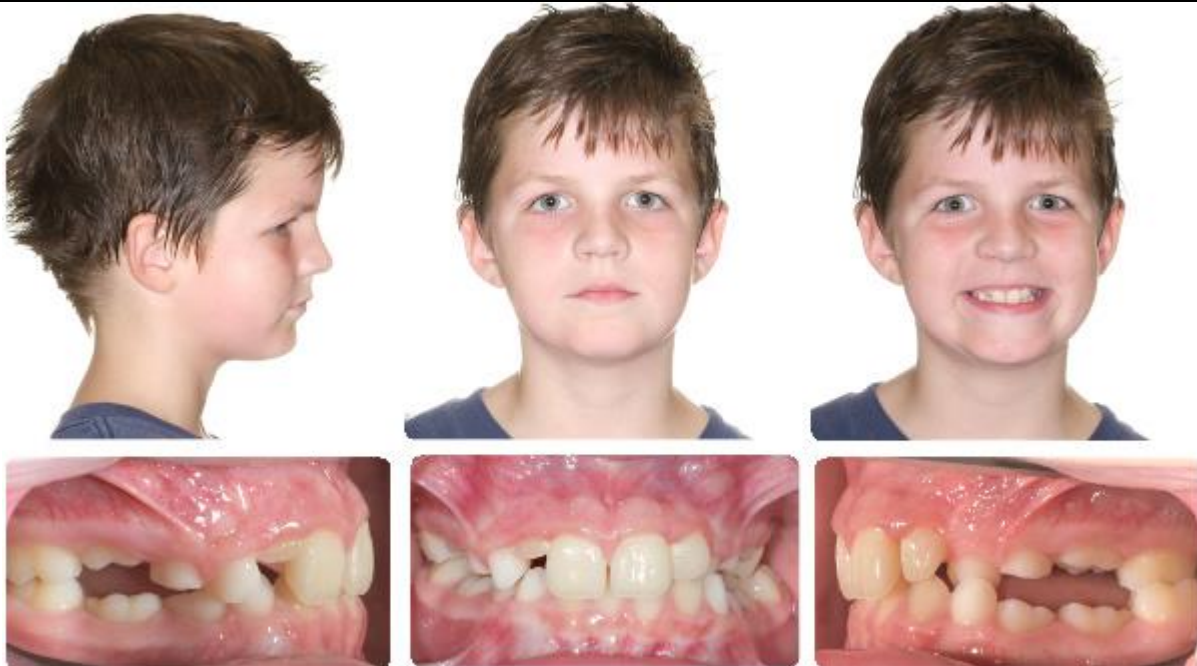




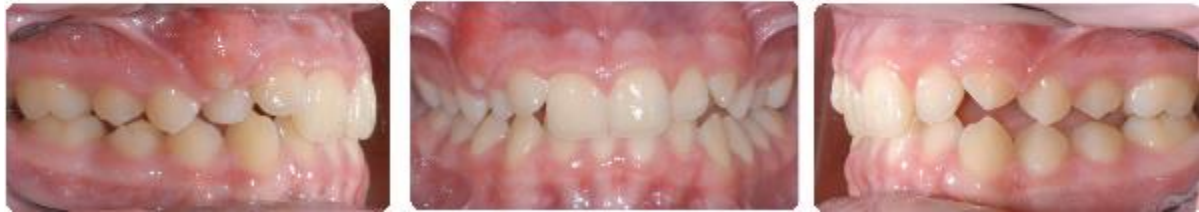


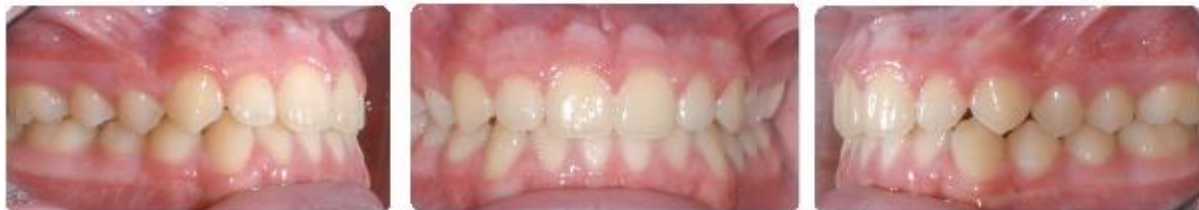After upper partial braces and Xbow with springs for 3 months followed by maxillary expansion Dr. McDonald removed third molars and exposed the impacted central incisor and right canine. Waiting for the upper second molars to erupt before determining the need for full braces



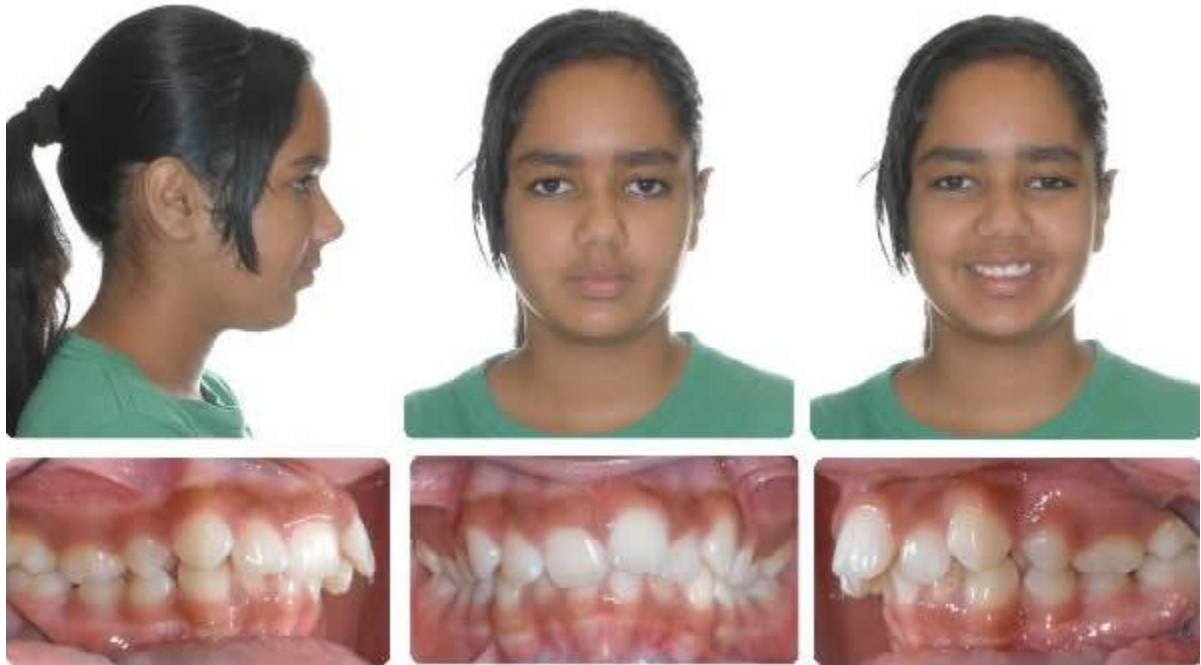initial



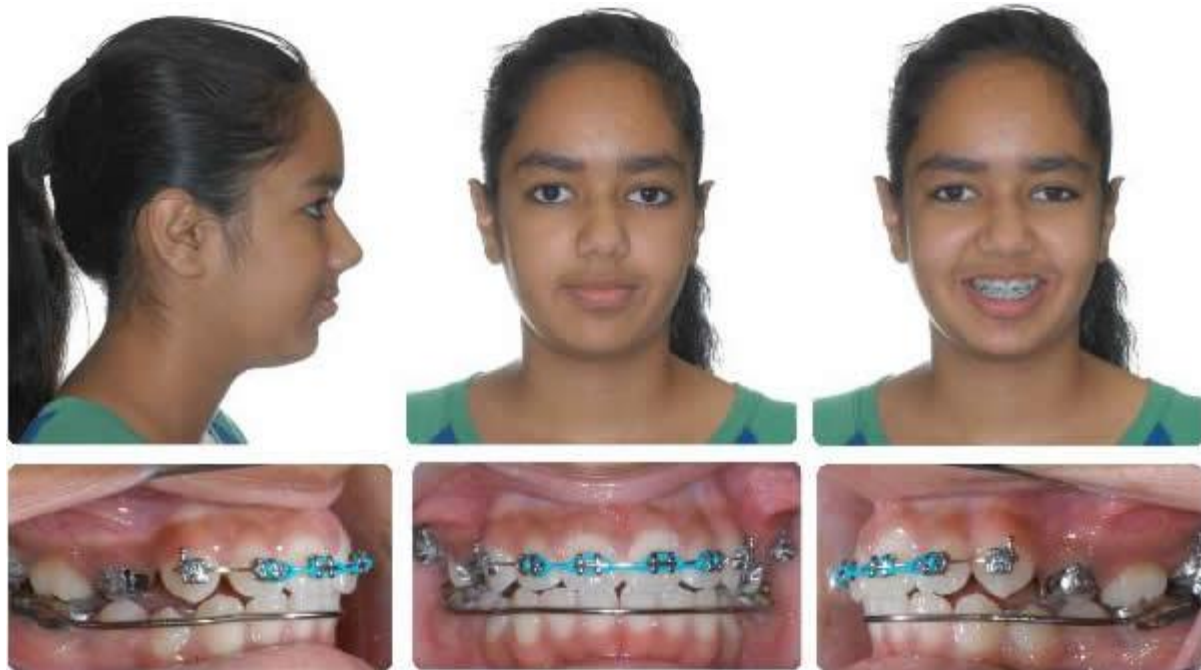2 years after maxillary expansion



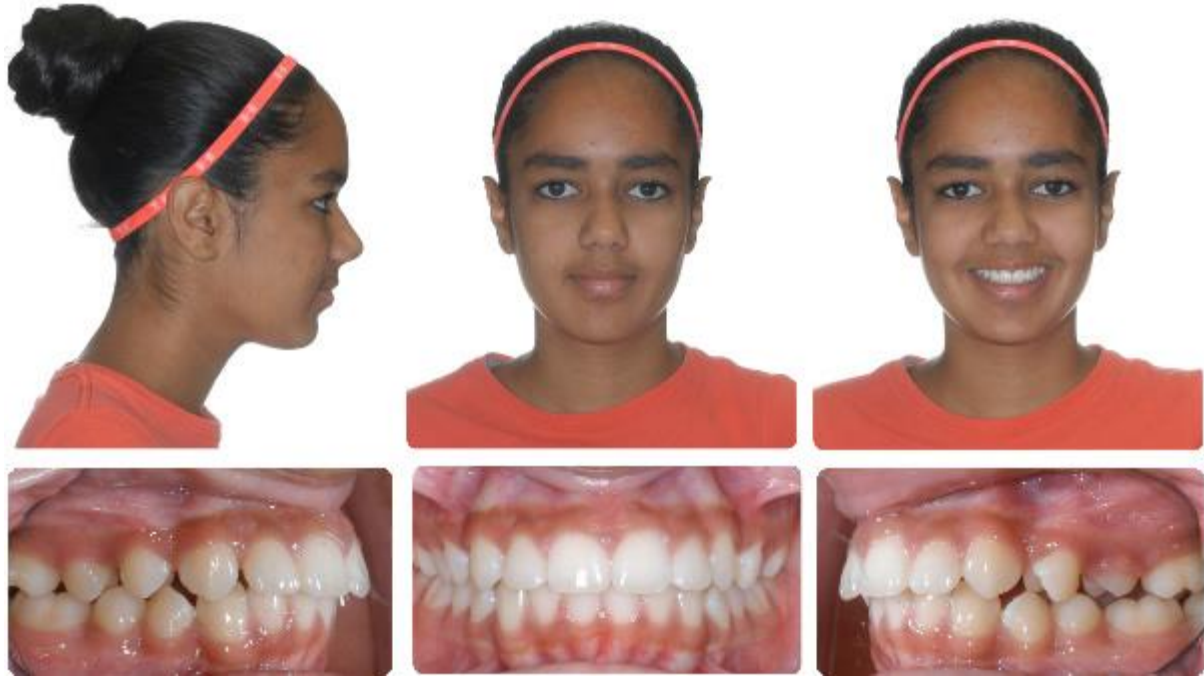partial upper braces and Xbow with springs for 3 months followed by maxillary expansion, full braces have not been used



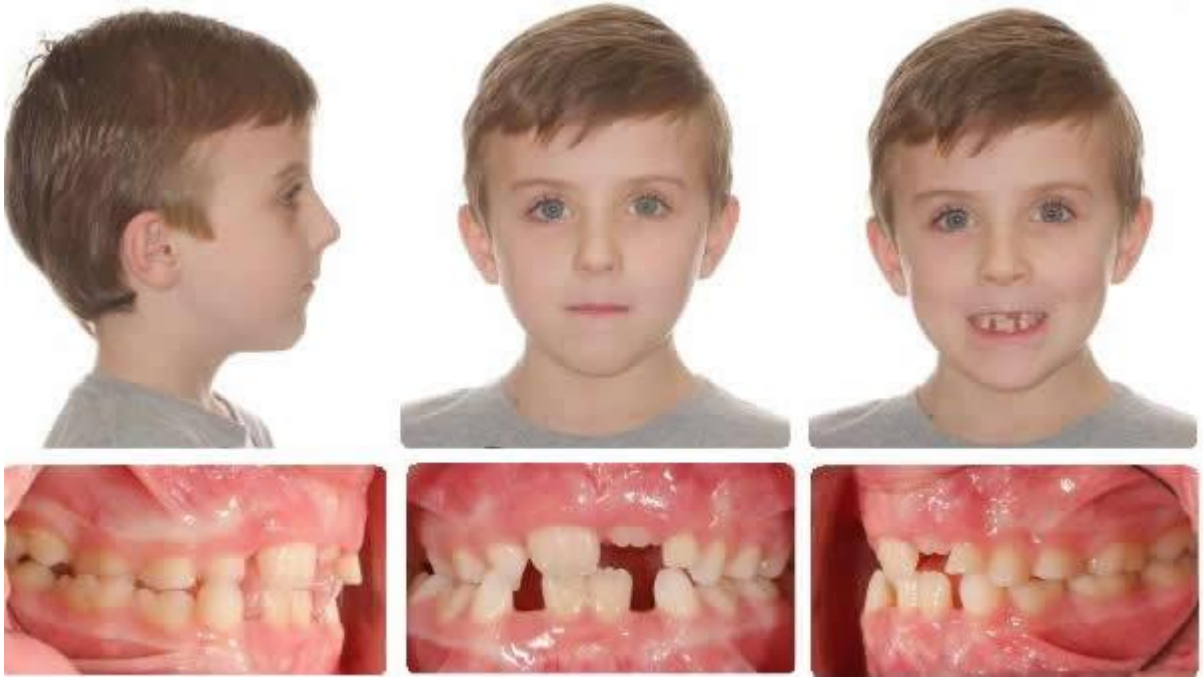Initial



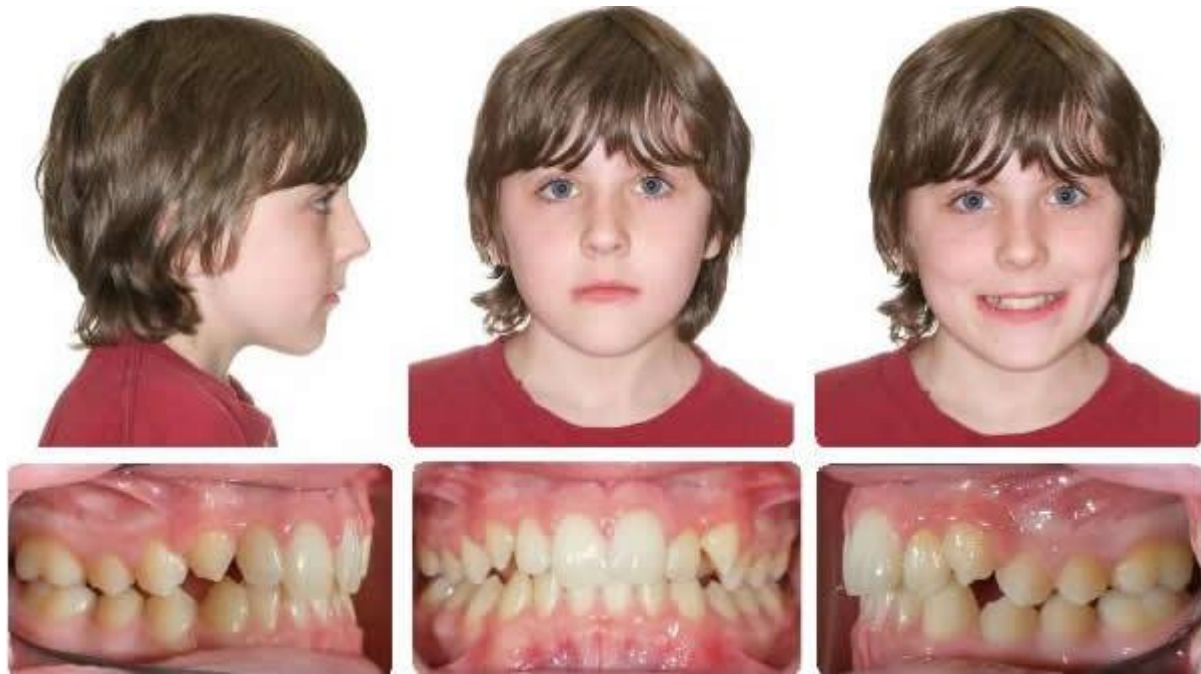Upper 2X6, 4 months Xbow, ready for maxillary expansion



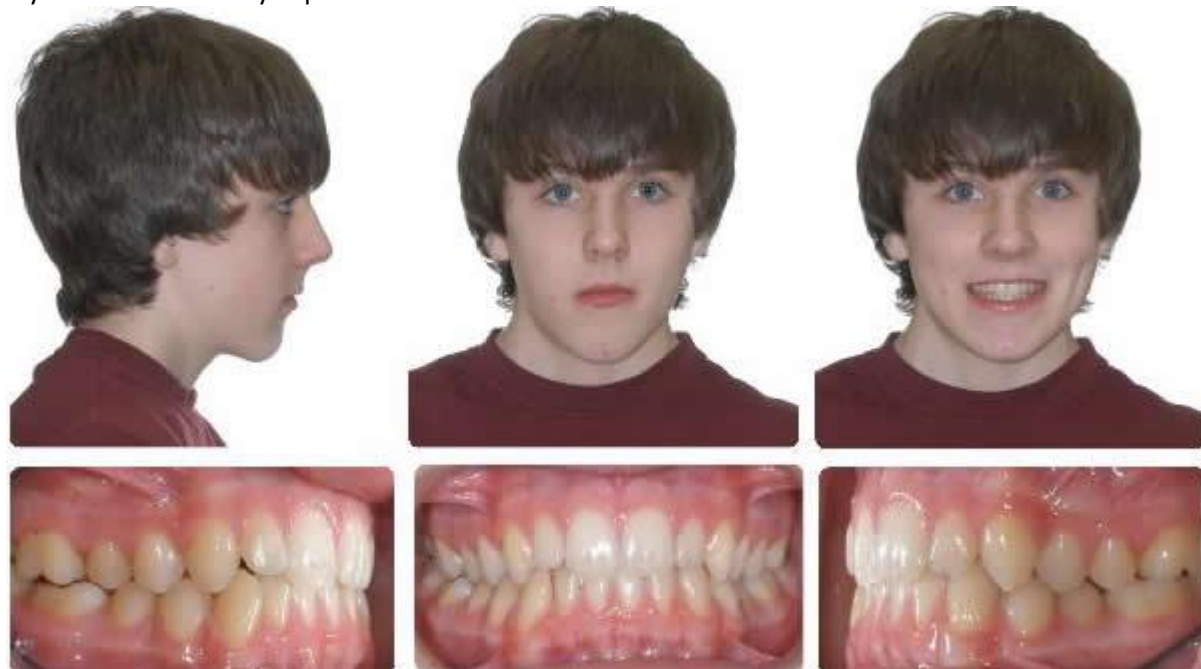11 months after spring removal, full braces have not been used



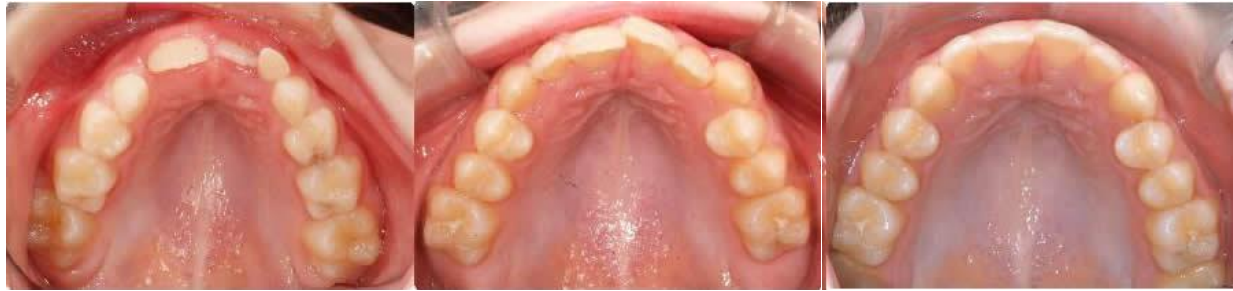Initial, posterior crossbite and anterior crowding



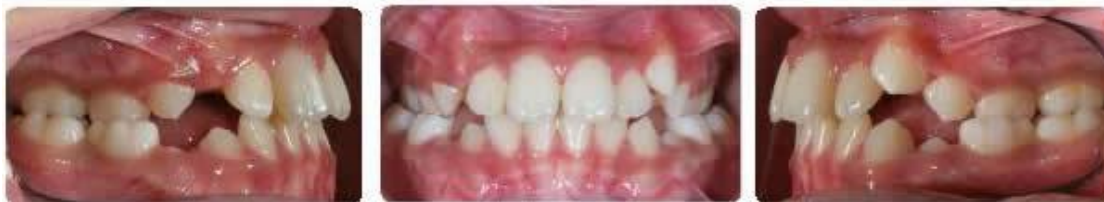4 years after maxillary expansion



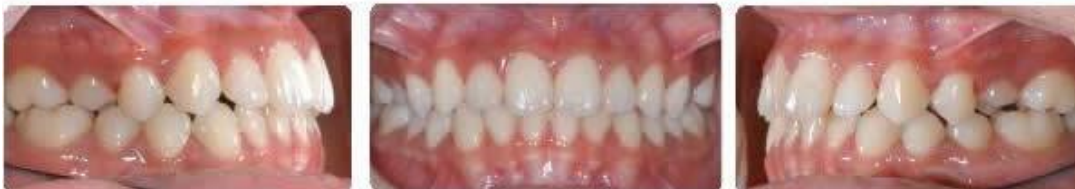Xbow® with springs removed after 3 months, followed by compensatory maxillary expansion, no braces used, photos taken 2 years after Xbow® removal



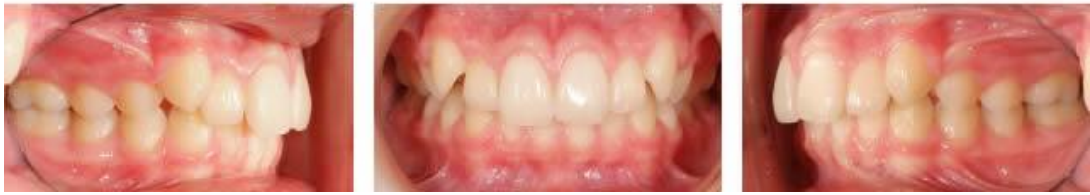Initial _____ 4 years after maxillary expansion _____ 2 years after Xbow, no braces used



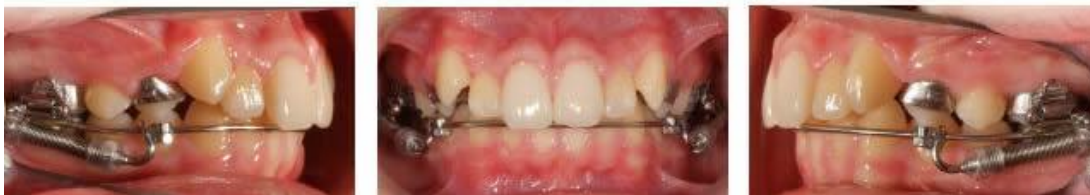initial



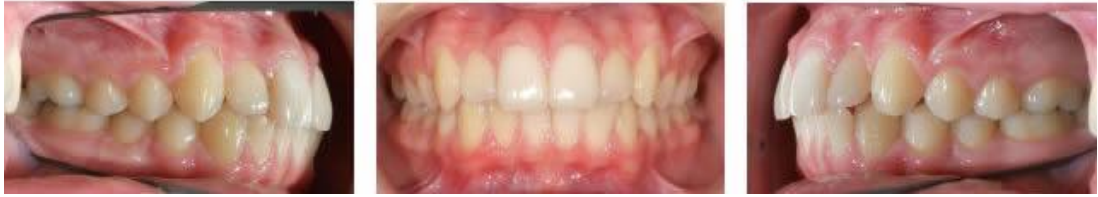1. RME 2. Xbow 3 months 3. RME



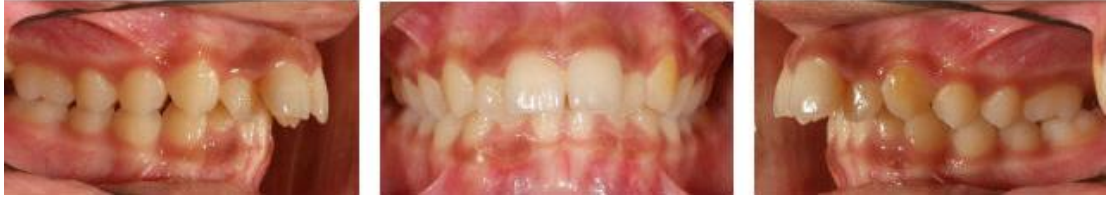Before



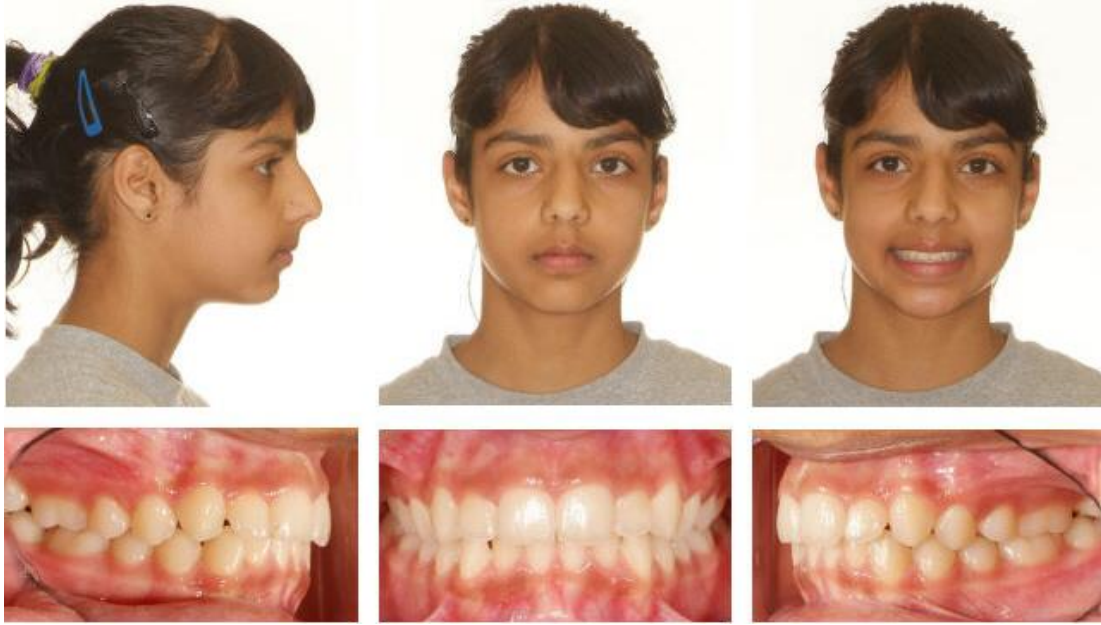Xbow



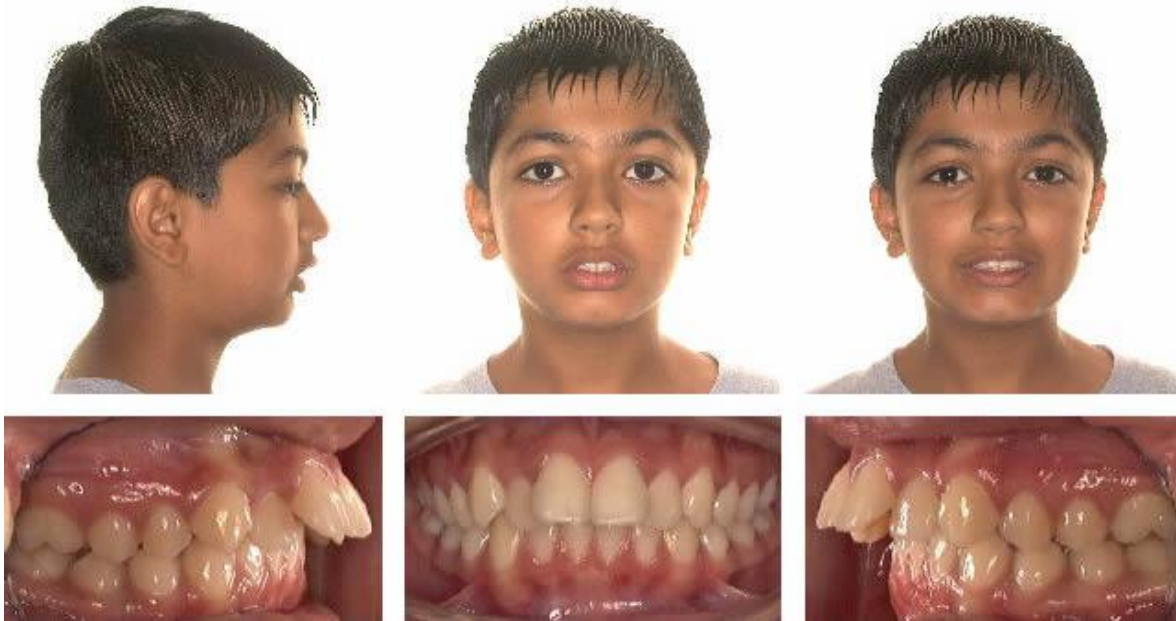Xbow 6 months. After photos taken 14 months after spring removal. No braces have been used.



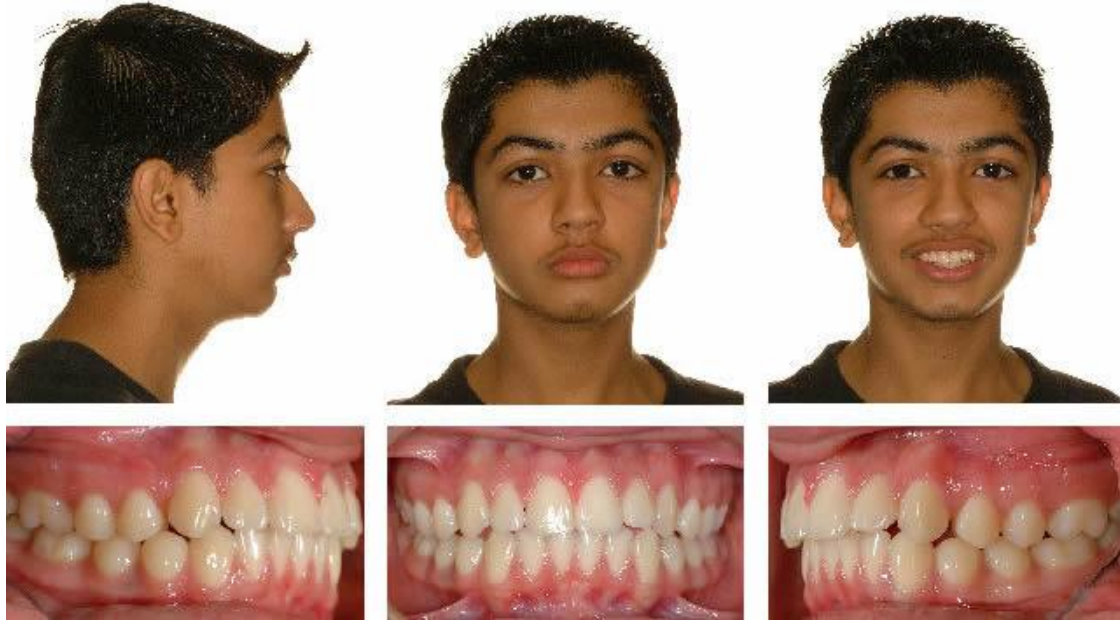Before



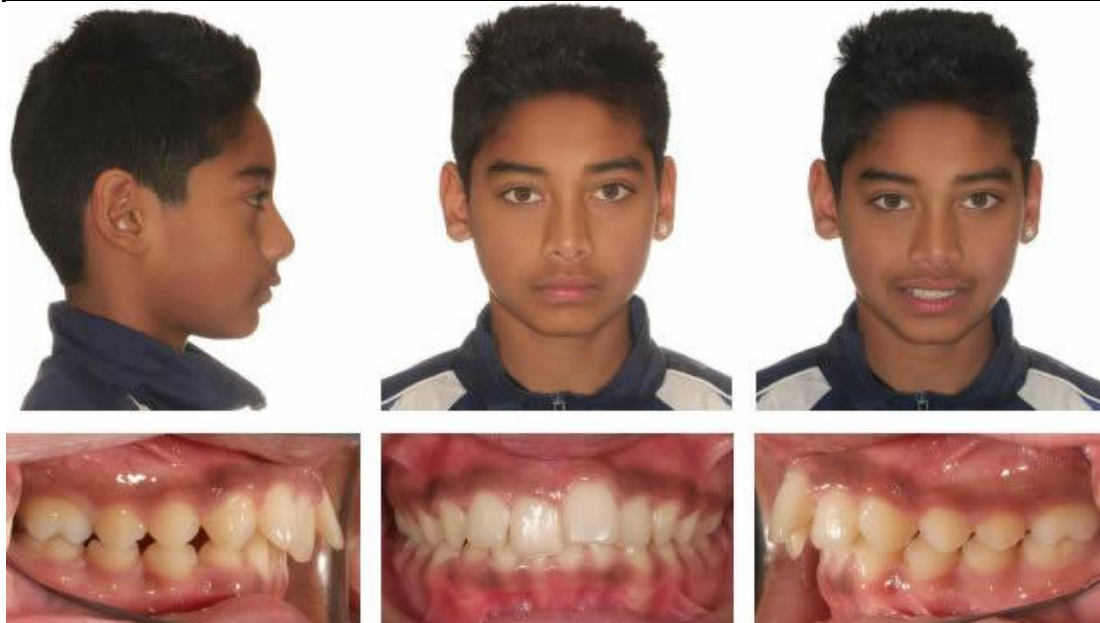1. Upper 2X4 (4 incisor brackets) 2. Xbow 4 months 3. RME (compensatory upper jaw expansion)
After photos taken 7 months after Forsus spring removal. Full braces were not used.



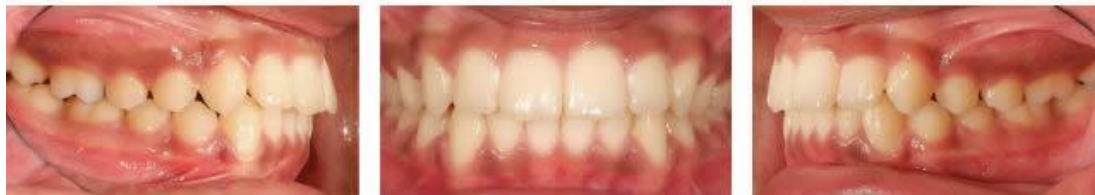Before



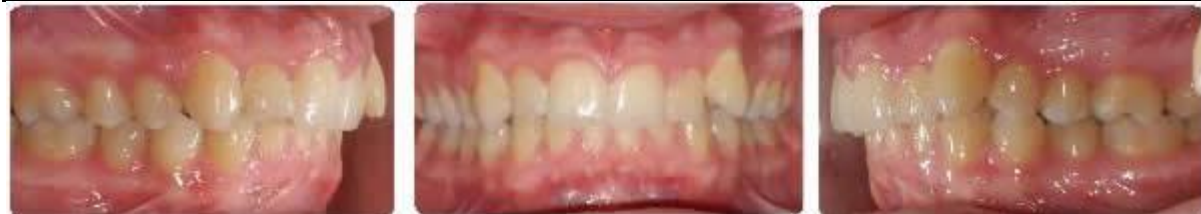1. Upper 2X4 (four incisor brackets) 2. Xbow 4 months (11 months after Forsus spring removal, Full braces have not been used)



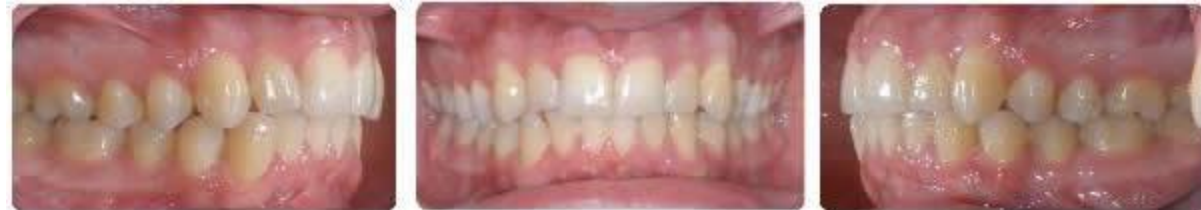Before



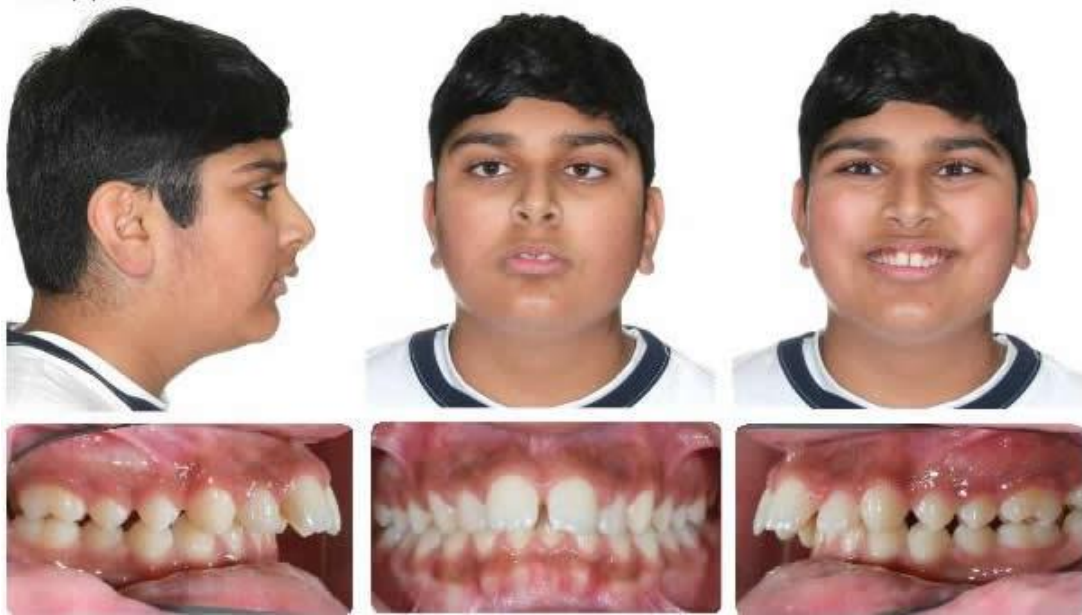1. Upper 2X4 (4 incisor brackets) 2. Xbow 4 months
(7 months after Forsus spring removal. Full braces have not been used)



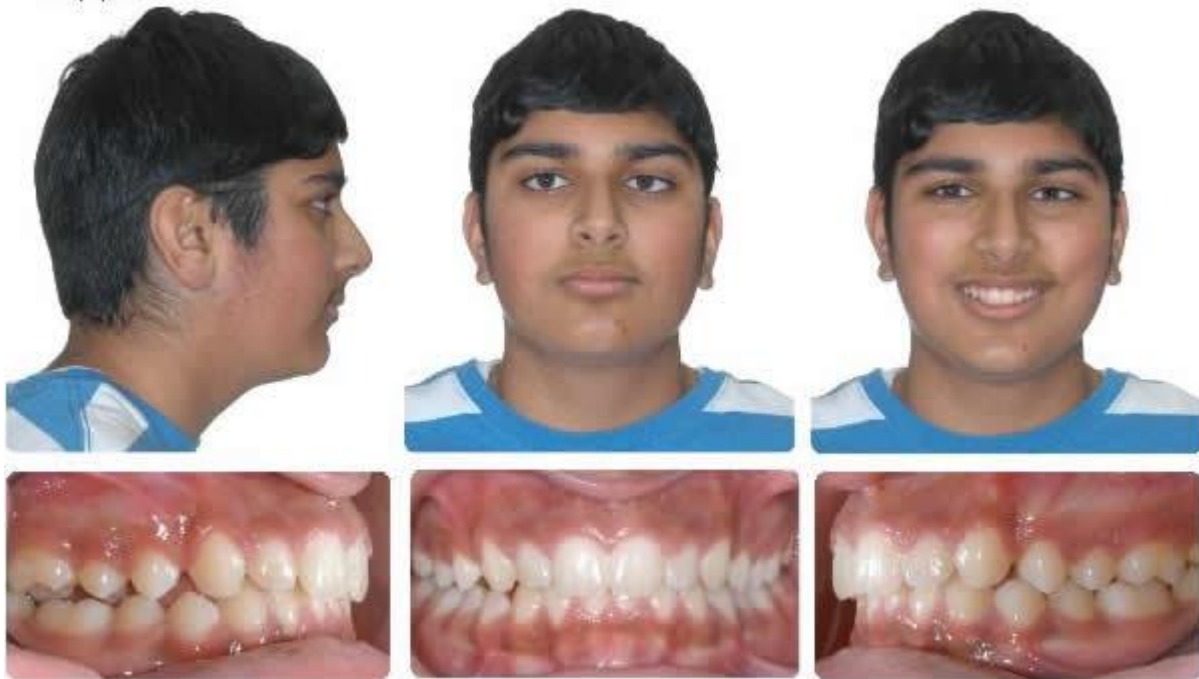Initial (first bicuspid relationship 1mm Class II right, 4mm Class II left)



Treated by Xbow only without any braces. Springs were placed on both sides for 4 months followed by compensatory maxillary expansion.
The left spring was replaced for 3 more months and then removed to allow rebound.
The appliance was debanded one month later.
The teeth were allowed to settle for an additional 2 months.



Initial



1.Xbow 4 months followed by compensatory maxillary expansion, 2. Replace right spring for 4 more months, Photos taken after 2 months settling.
