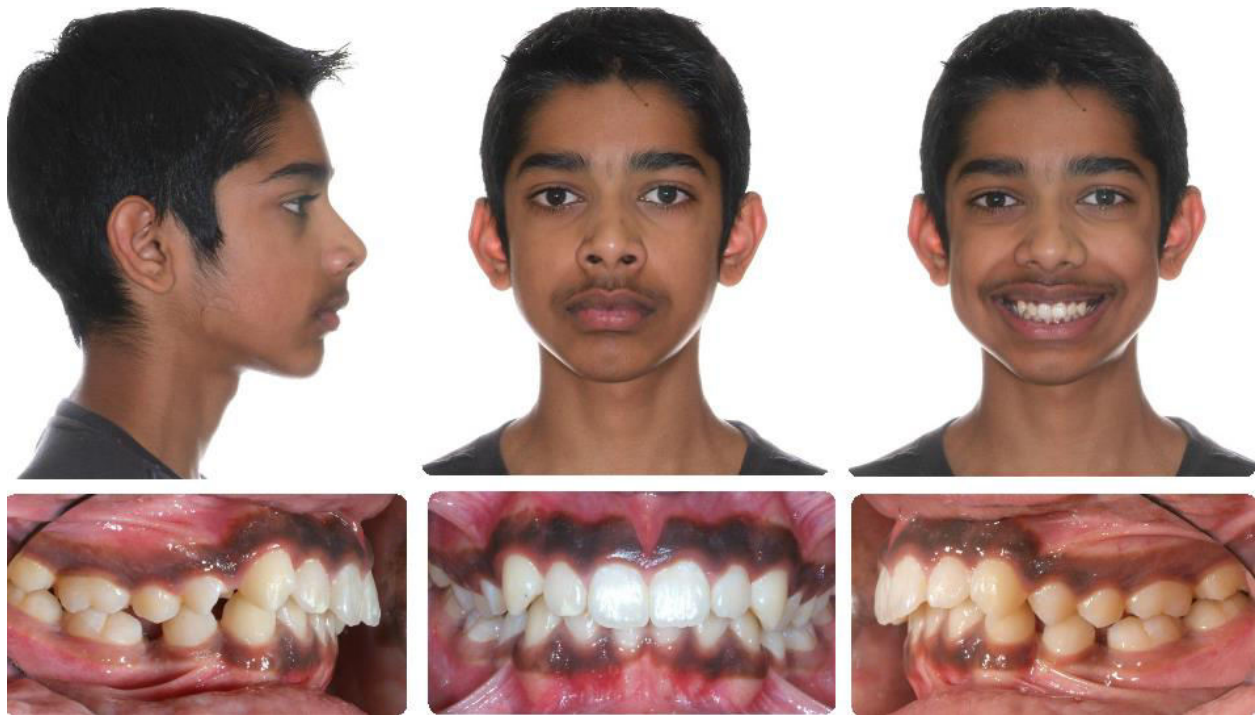
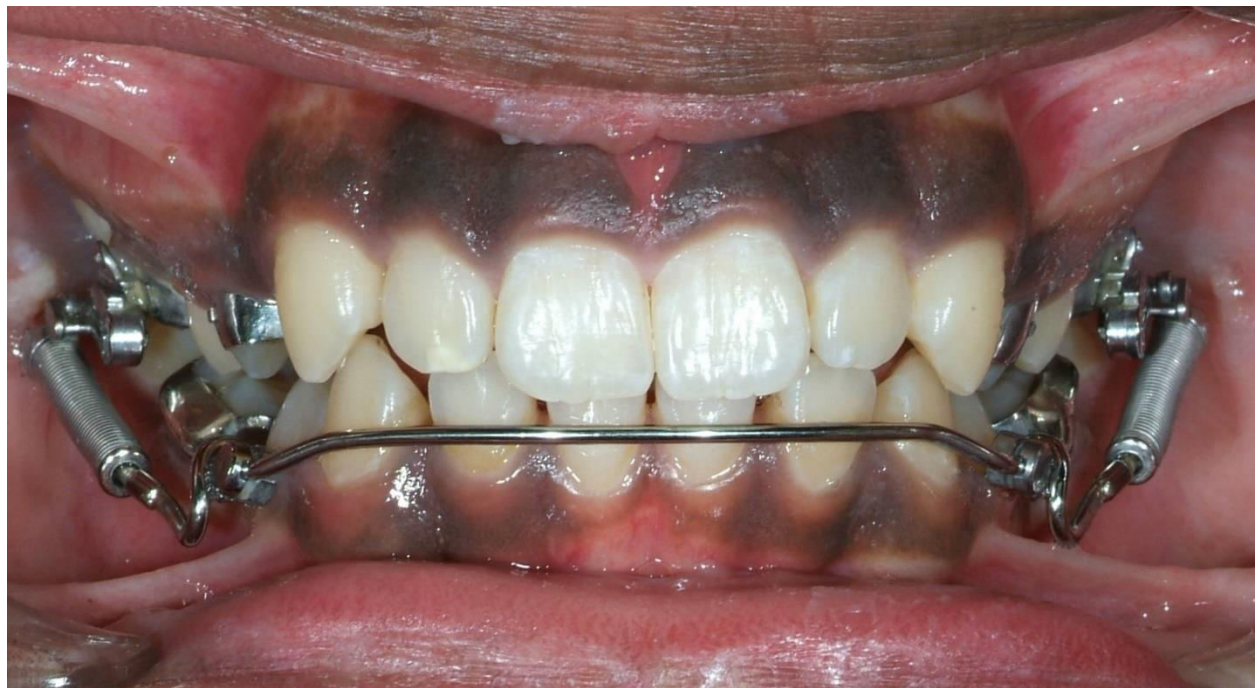
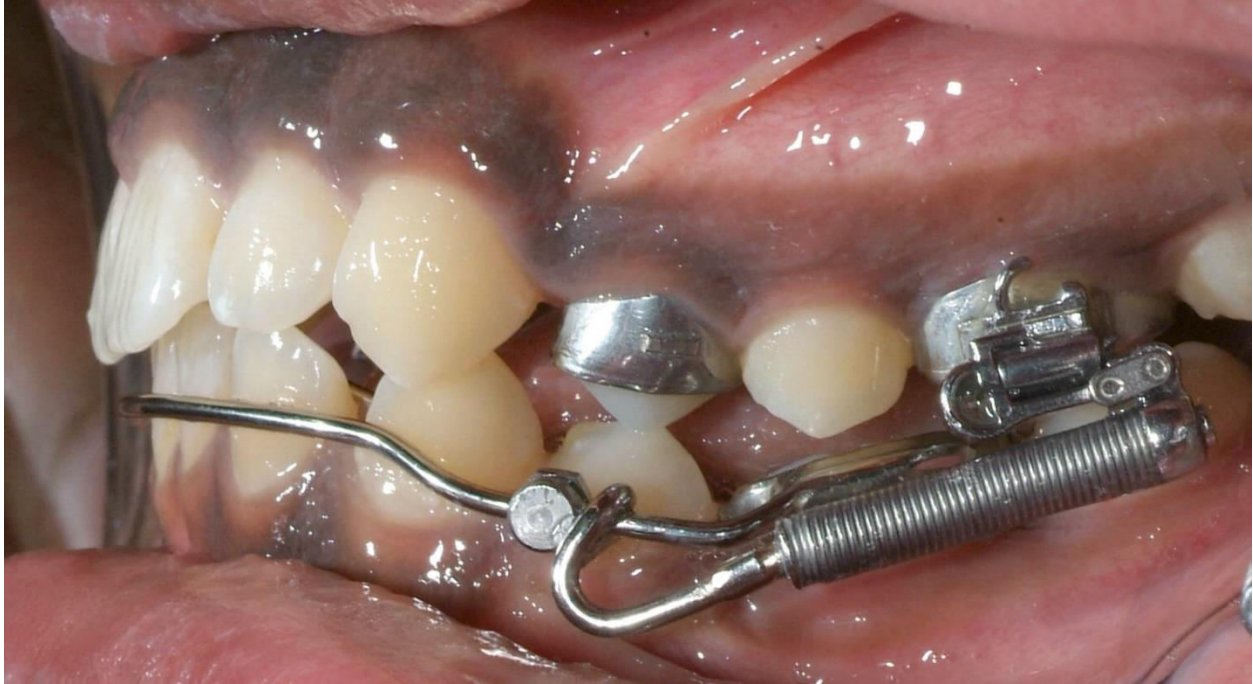Missing Lower Second Bicuspid: A Case for Crossbow



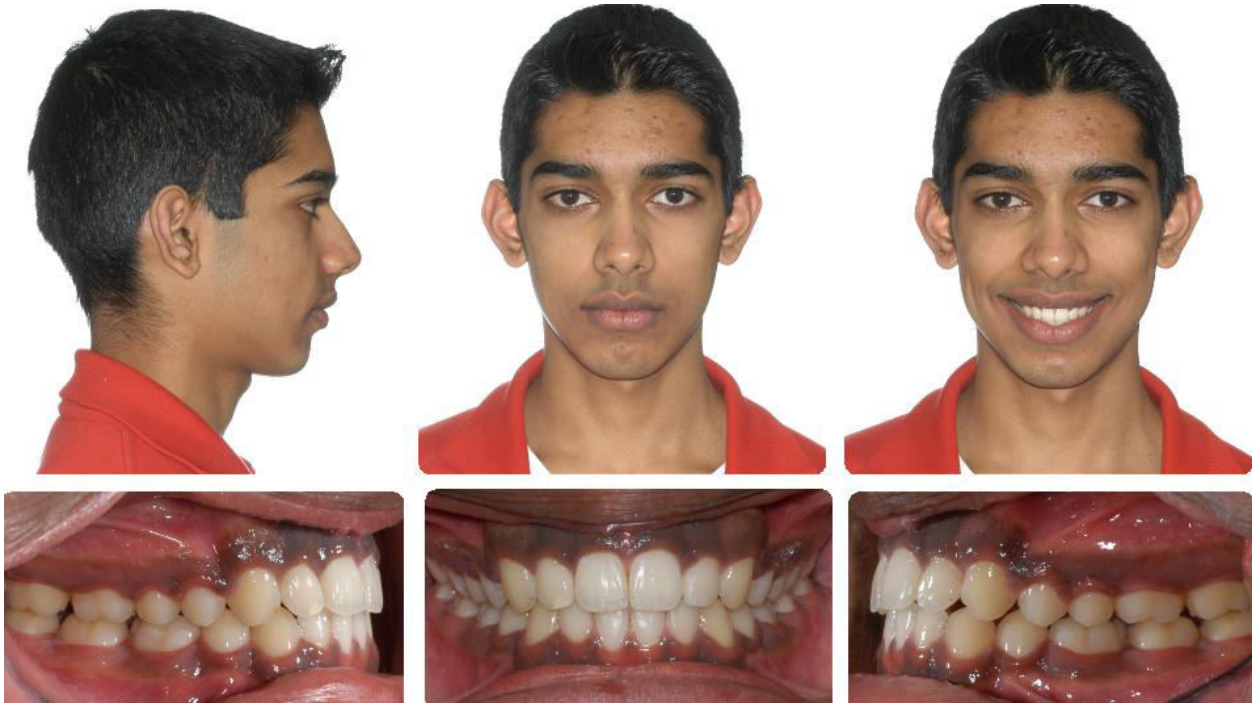
Missing lower second bicuspids, lower primary second molars were removed early to allow molar drifting and early eruption of lower second and third molars



Crossbow with springs and 29mm pushrods with bayonet bends



29mm pushrods



After Crossbow with springs for 4 months, followed by compensatory maxillary expansion, followed by 15 months full braces, lower third molars in occlusion